



B-CELL LYMPHOMAS: WHAT'S NEW?

Haematopathology Workshop

Jointly Organized By College Of Pathologists Of Sri Lanka
And Sri Lanka College Of Haematologists, 17th January
2019, Medical Research Institute Colombo

A/Prof Ng Siok Bian
Department of Pathology
National University of Singapore

CONTENT

- Lymphoplasmacytic lymphoma (LPL)
- Pediatric nodal marginal zone lymphoma (pNMZL)
- Pediatric Follicular lymphoma (pFL)
- LBCL with IRF4 rearrangement
- EBV-positive DLBCL NOS
- Mucocutaneous ulcer (MCU)
- Burkitt like lymphoma (BLL) with 11q abnormalities
- High grade B cell lymphoma (HGBCL)

ORIGINAL ARTICLE

MYD88 L265P Somatic Mutation in Waldenström's Macroglobulinemia

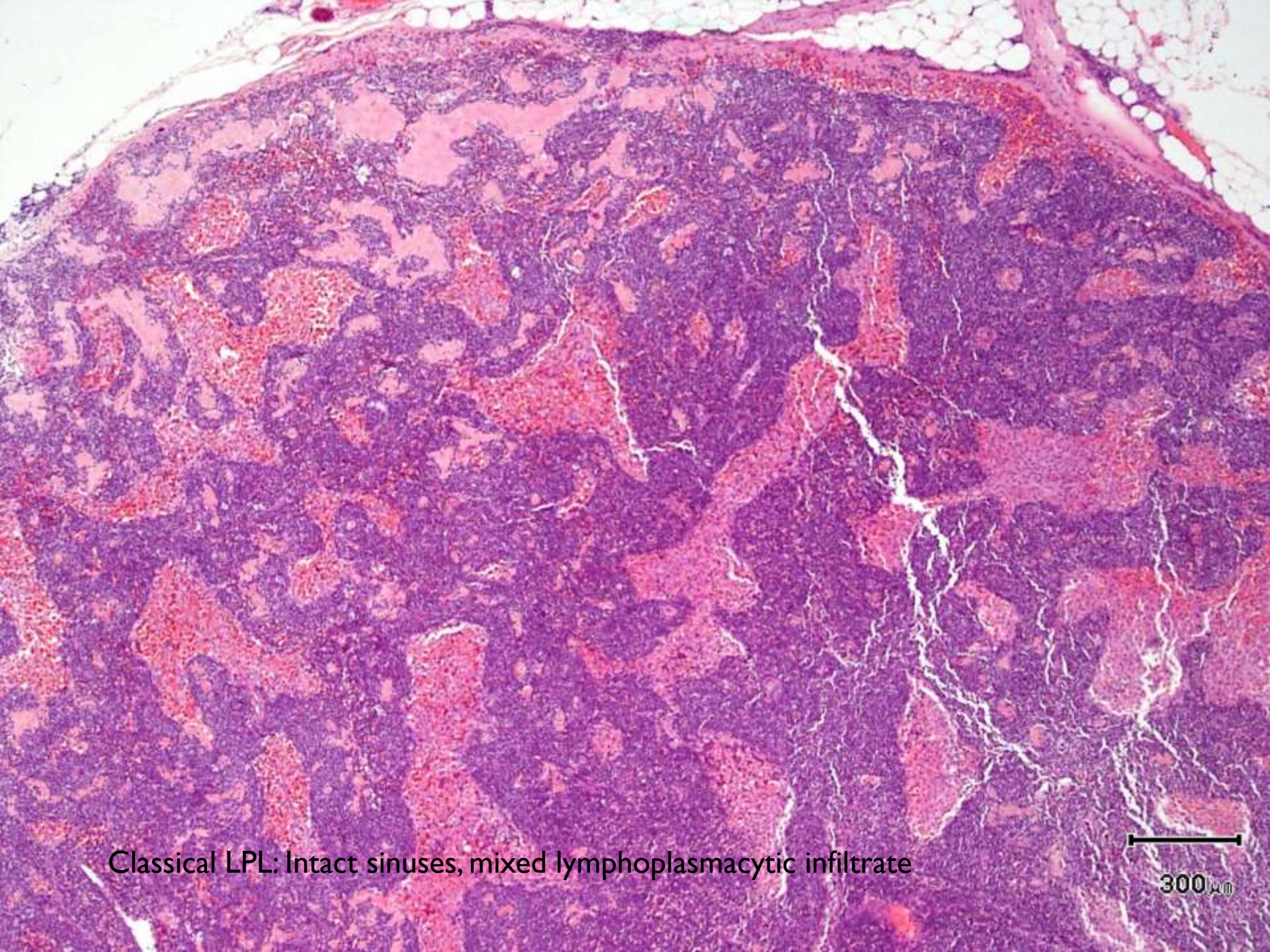
Steven P. Treon, M.D., Ph.D., Lian Xu, M.S., Guang Yang, Ph.D.,
Yangsheng Zhou, M.D., Ph.D., Xia Liu, M.D., Yang Cao, M.D.,
Patricia Sheehy, N.P., Robert J. Manning, B.S., Christopher J. Patterson, M.A.,
Christina Tripsas, M.A., Luca Arcaini, M.D., Geraldine S. Pinkus, M.D.,
Scott J. Rodig, M.D., Ph.D., Aliyah R. Sohani, M.D., Nancy Lee Harris, M.D.,
Jason M. Laramie, Ph.D., Donald A. Skifter, Ph.D., Stephen E. Lincoln, Ph.D.,
and Zachary R. Hunter, M.A.

LYMPHOPLASMACYTIC LYMPHOMA

- 90% of LPL/WM contain MYD88 mutation (diagnostic marker for LPL)(previously LPL diagnosis of exclusion)
- Revision of morphologic criteria of LPL based on MYD88 mutation
 - Classical LPL: Intact sinuses, mixed lymphoplasmacytic infiltrate, hemosiderin deposits
 - Includes LPL with atypical features
 - diffuse architecture with obliteration of sinuses, follicular colonization, no plasmacytoid differentiation but clg present, predominantly plasma cells
 - ‘polymorphic’ LPL without MYD88 mutation: excluded
 - IgM MGUS probably more related to LPL than MM

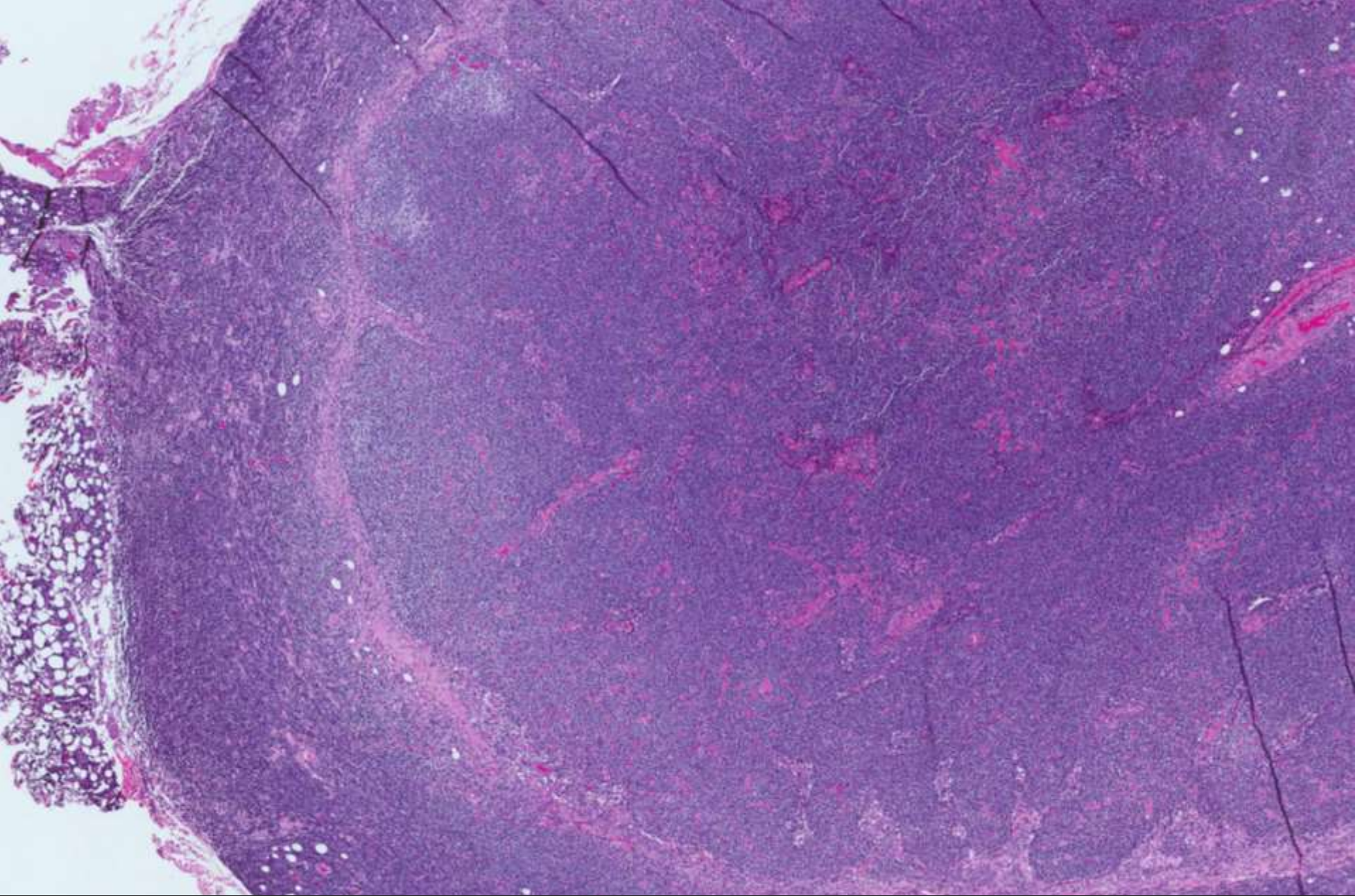
MYD88 MUTATION

- *MYD88* mutation is uncommon in other low- grade B-cell neoplasms (but is common in ABC type diffuse large B-cell lymphoma)
 - >90% WM/LPL
 - 47% IgM MGUS (higher levels of IgM paraprotein and risk of progression to WM and MZL)
 - 30% DLBCL-ABC
 - 9% MALT
 - 0-6% SMZL
 - 6% NMZL
 - 3% CLL
 - 4% chronic B-LPD
- a/W IgM monoclonal protein and BM involvement

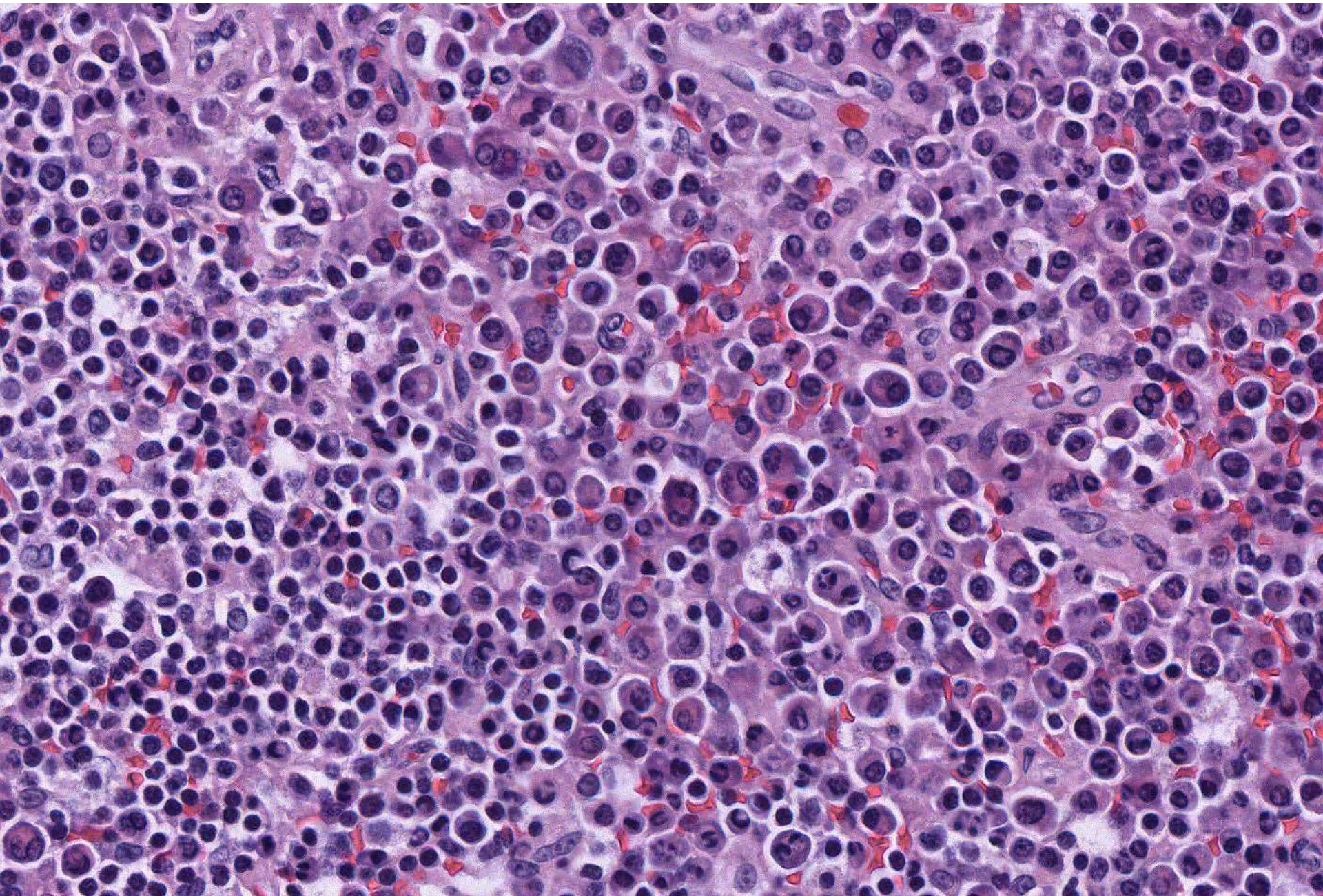


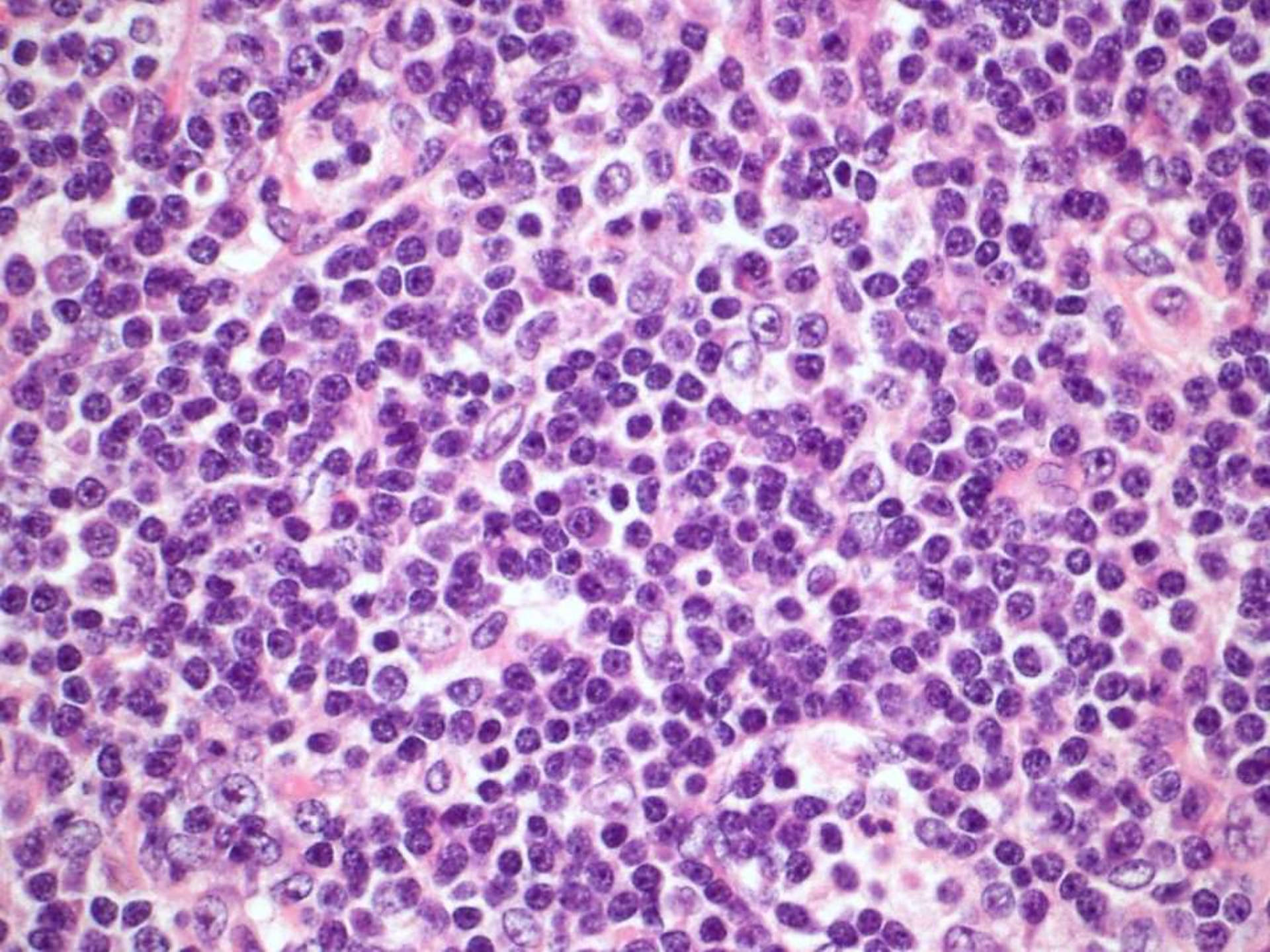
Classical LPL: Intact sinuses, mixed lymphoplasmacytic infiltrate

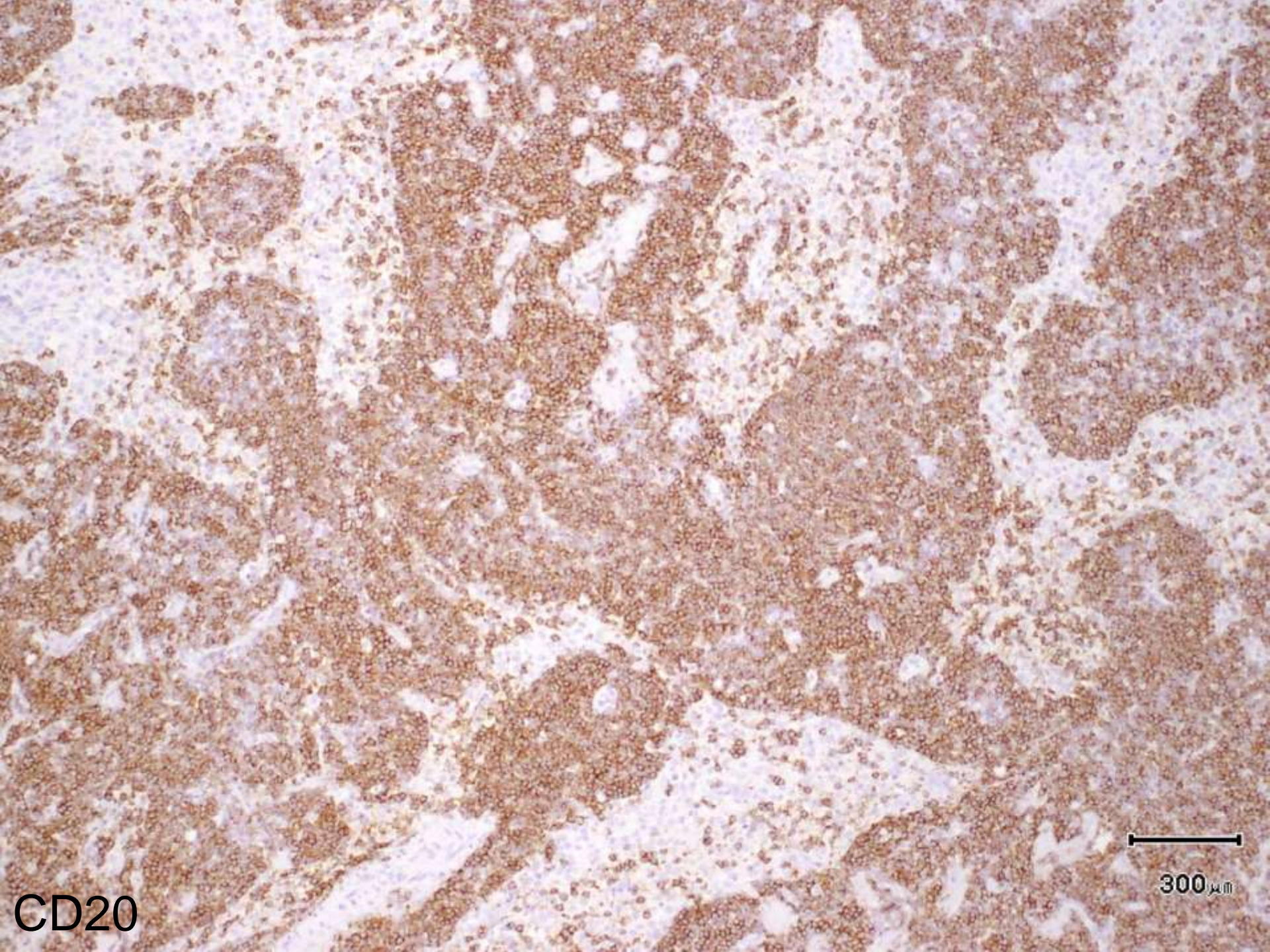
300 μ m



LPL with atypical features (diffuse pattern, extracapsular extension, sinusoidal obliteration)



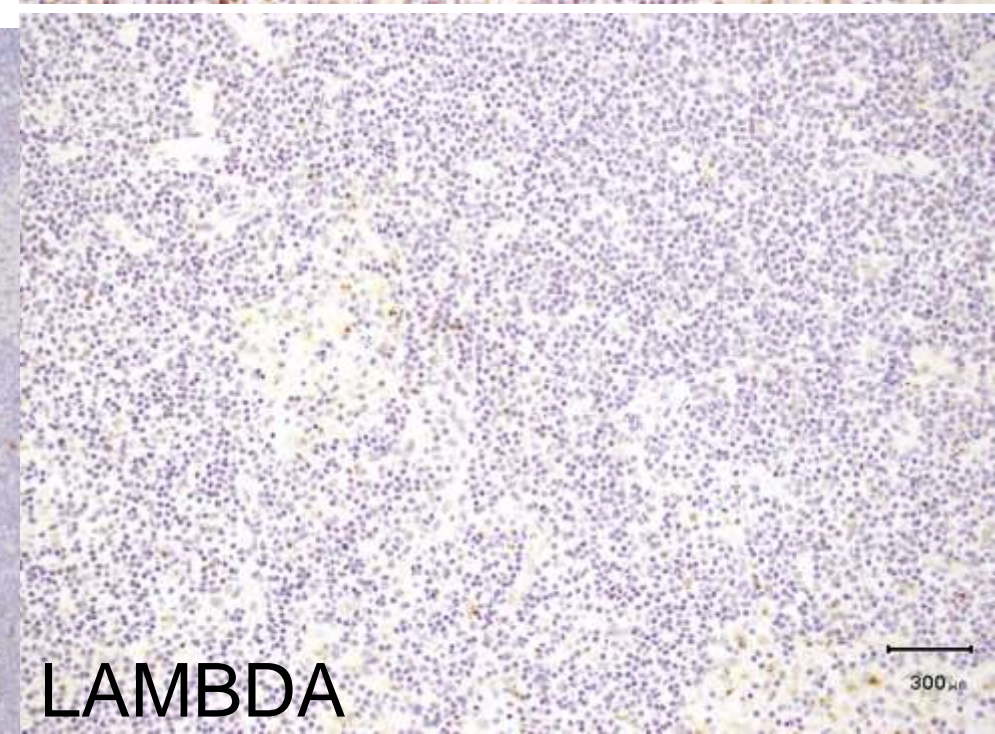
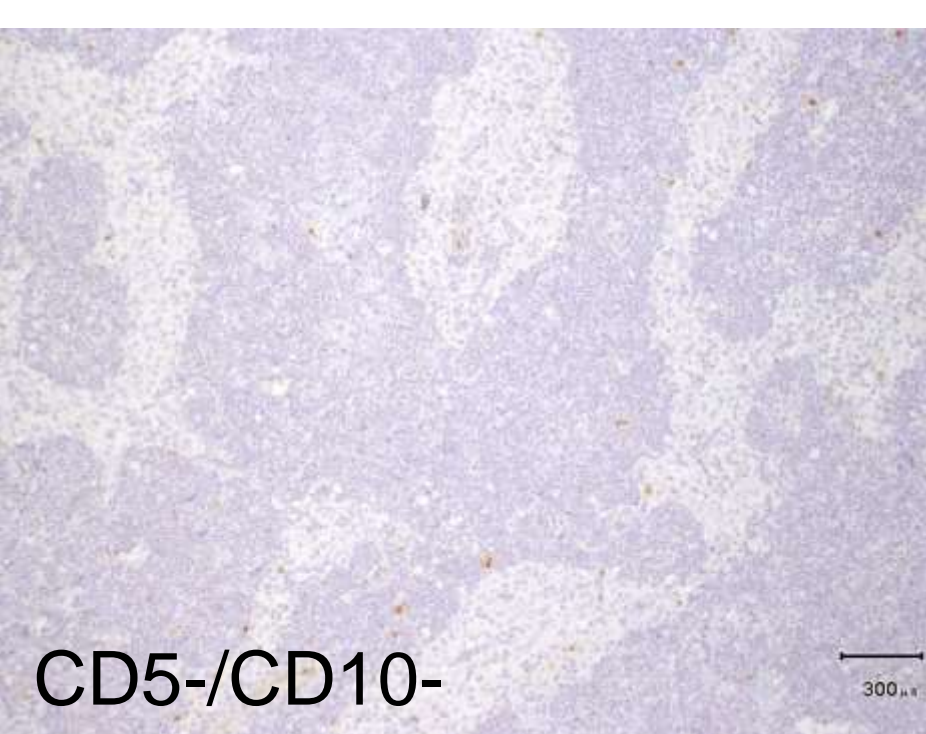
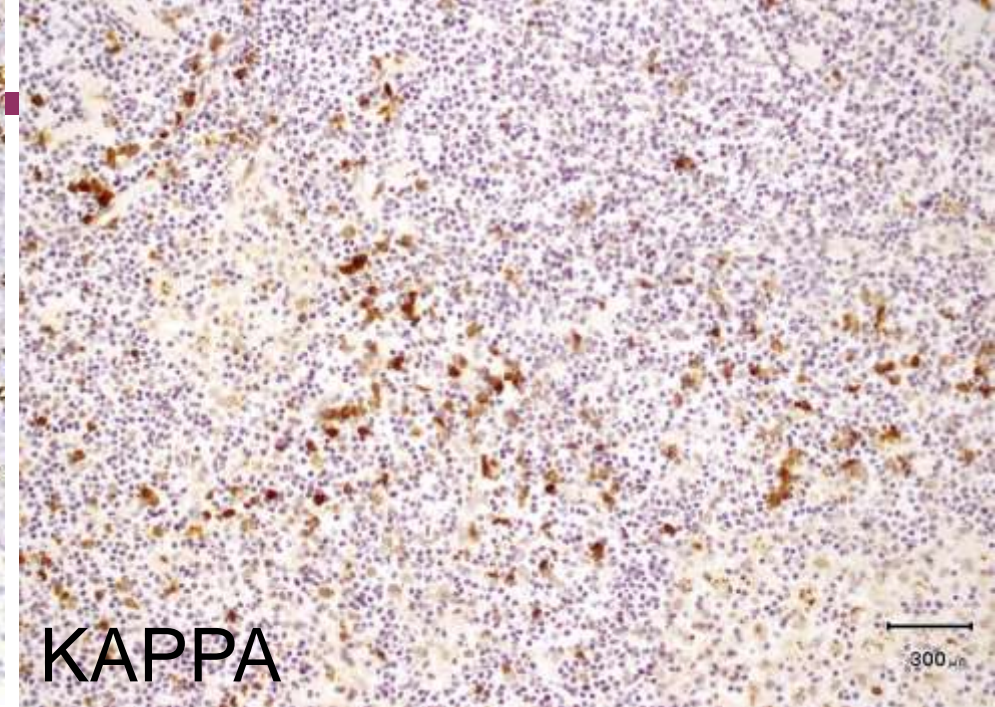
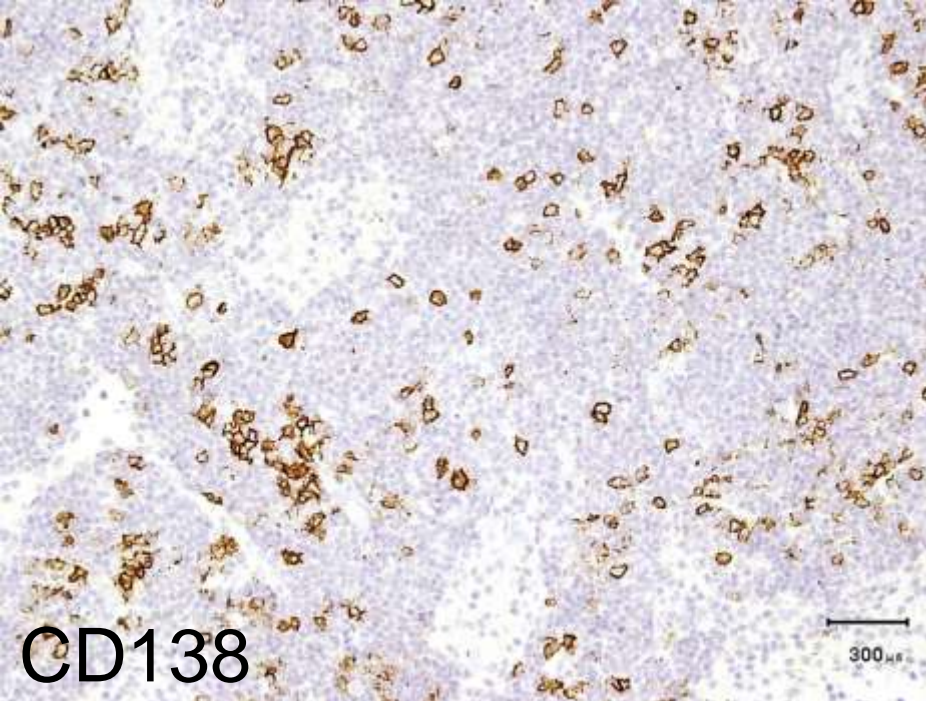




CD20

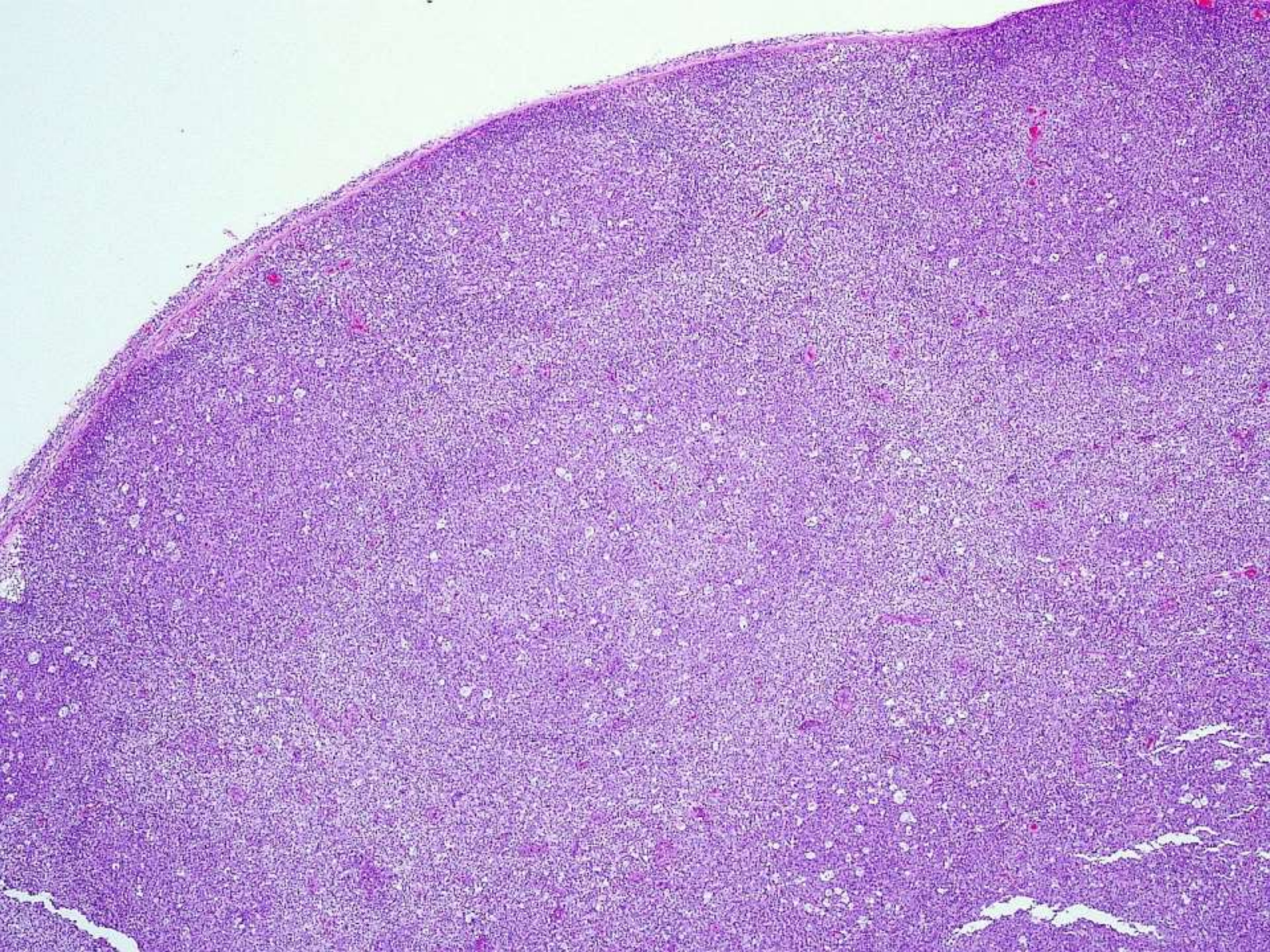


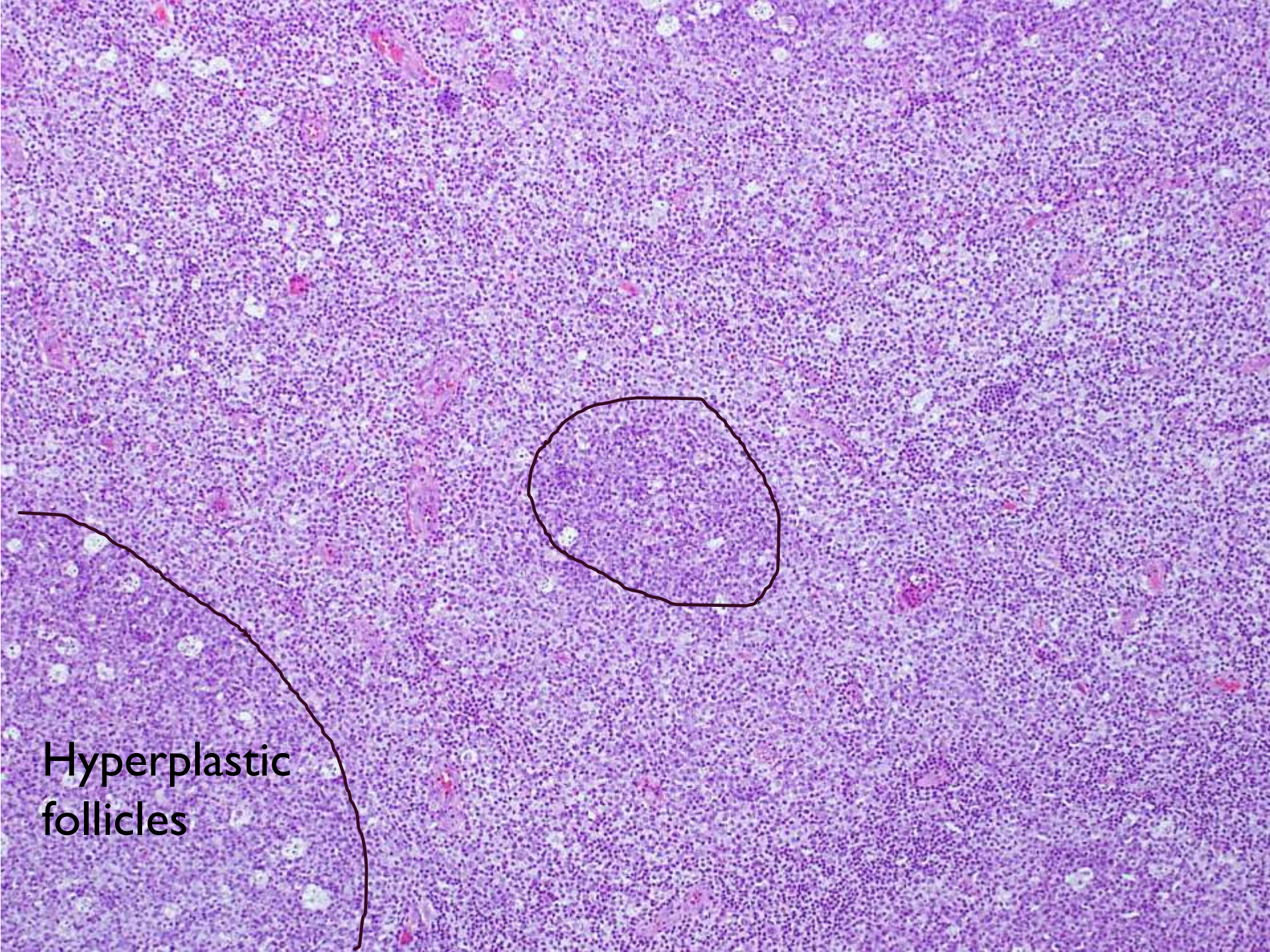
300 μ m



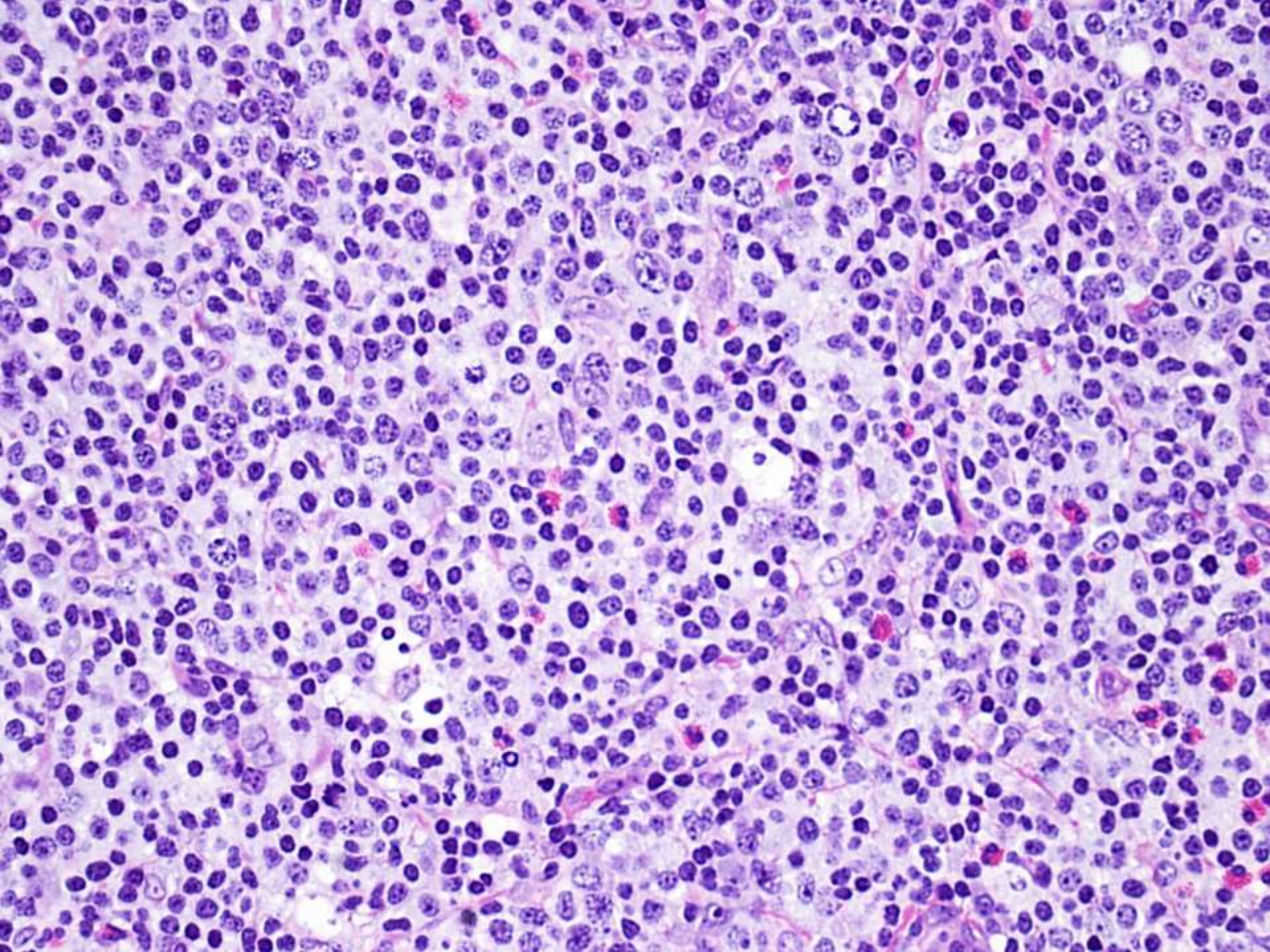
CASE 1 - HISTORY

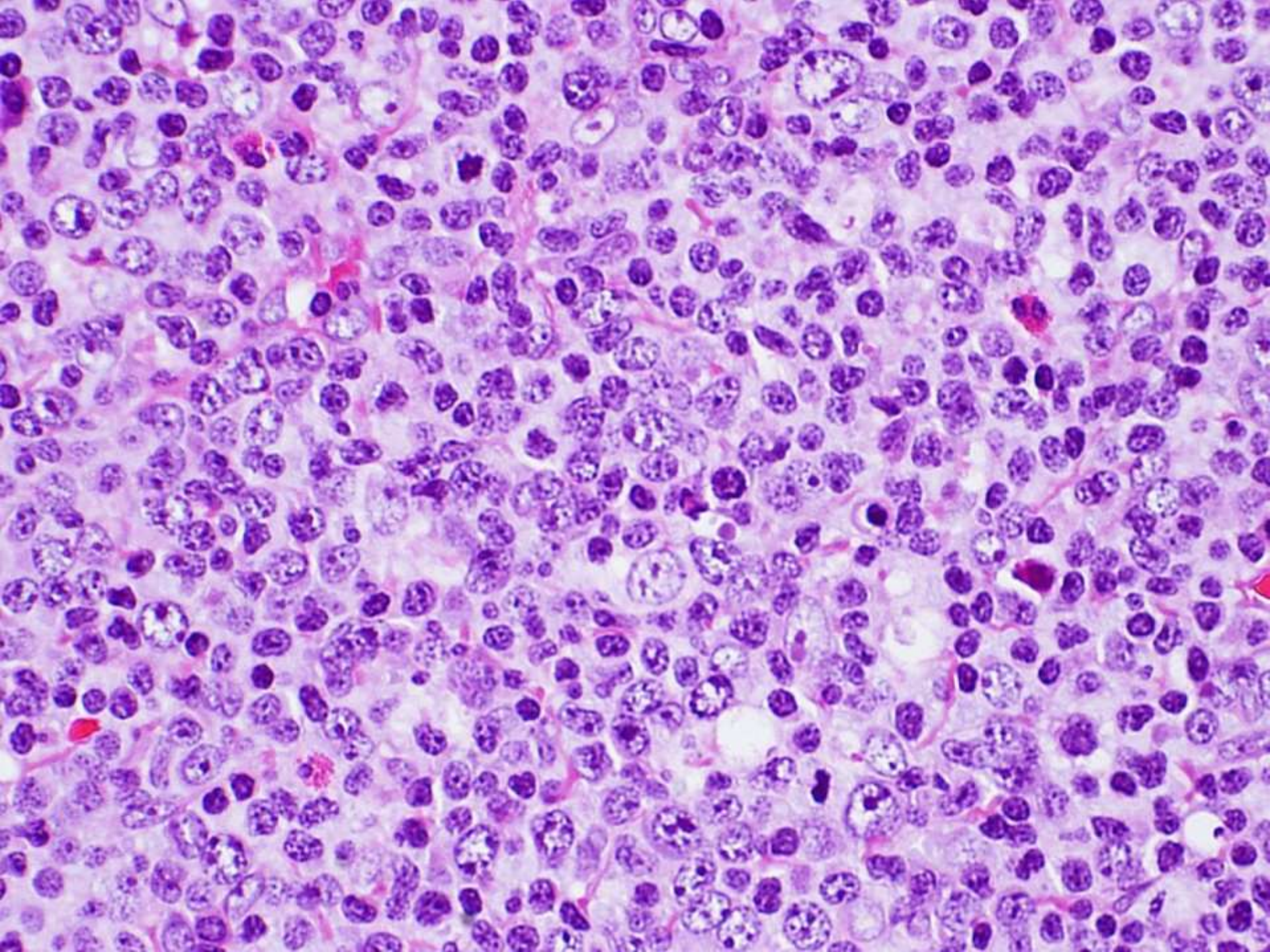
- A 15 year old male presented with slow growing left thigh swelling for 2 years
- No B symptoms.
- Biopsy of left inguinal node done
- PET scan revealed enlarged lymph node localised to left inguinal, iliac and obturator nodes.
- Stage I disease.
- Watchful wait management.

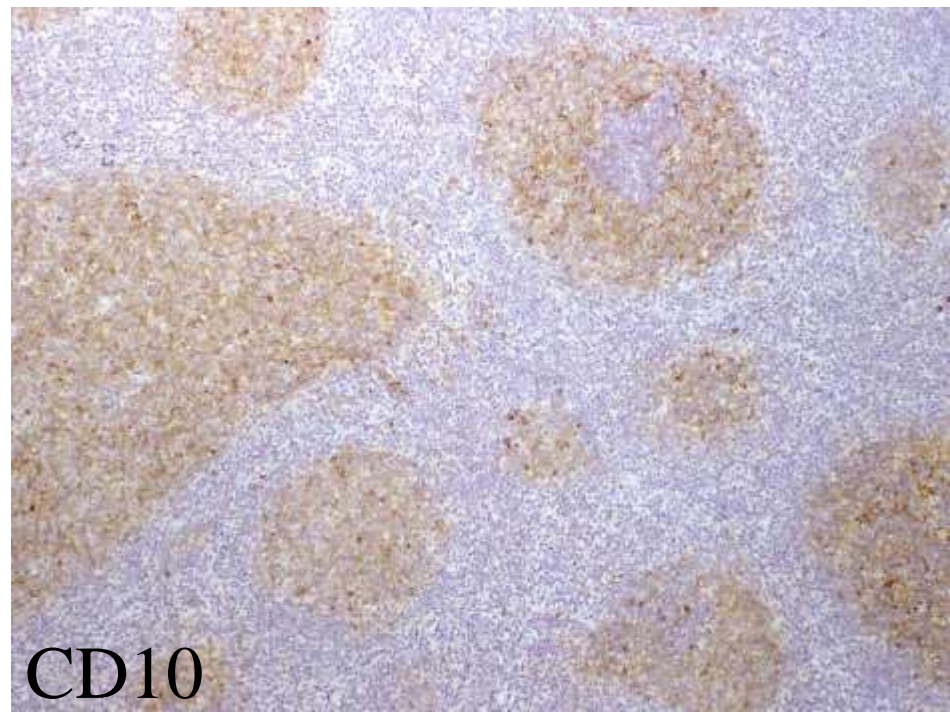
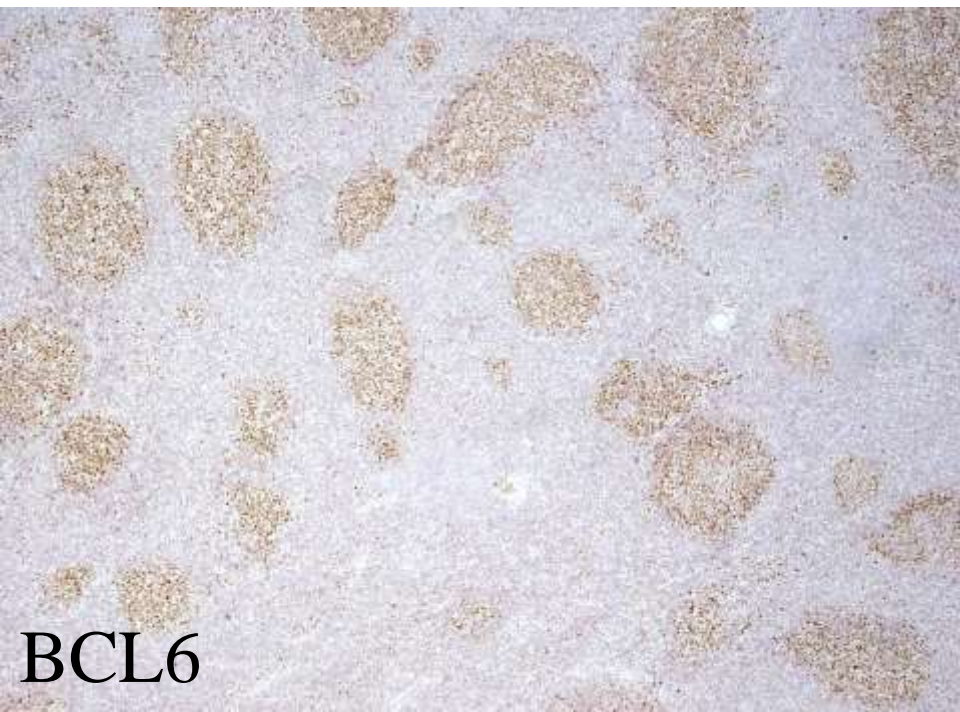
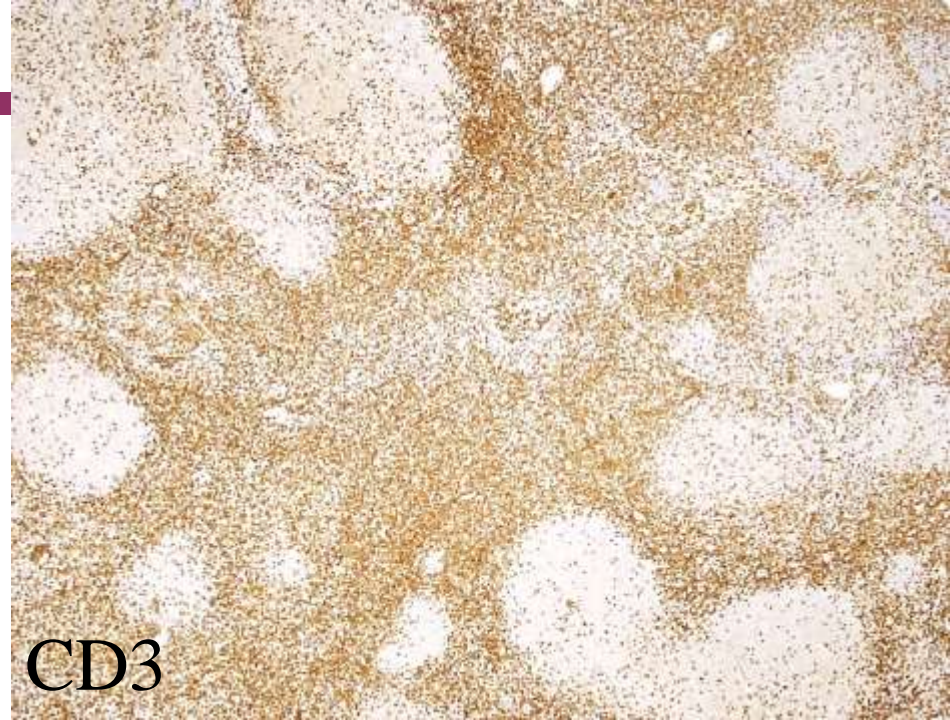
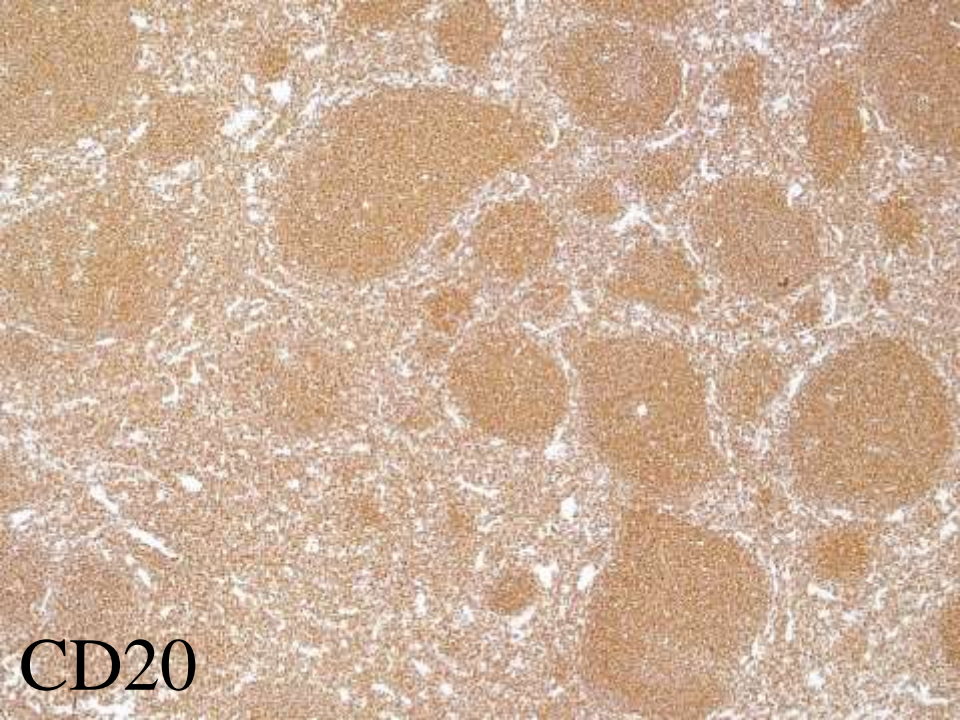


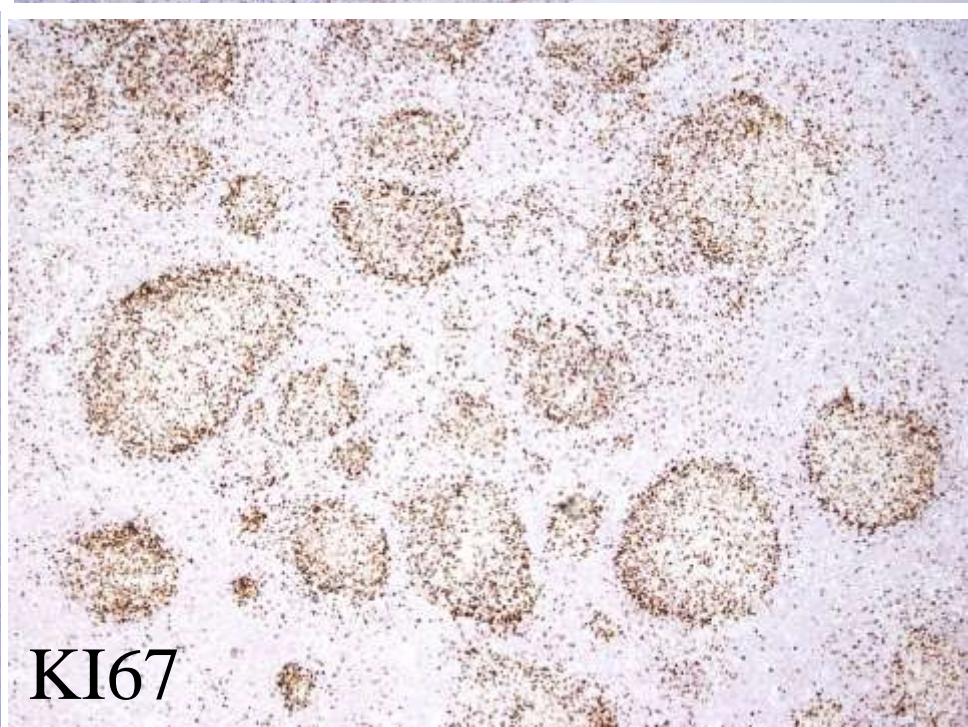
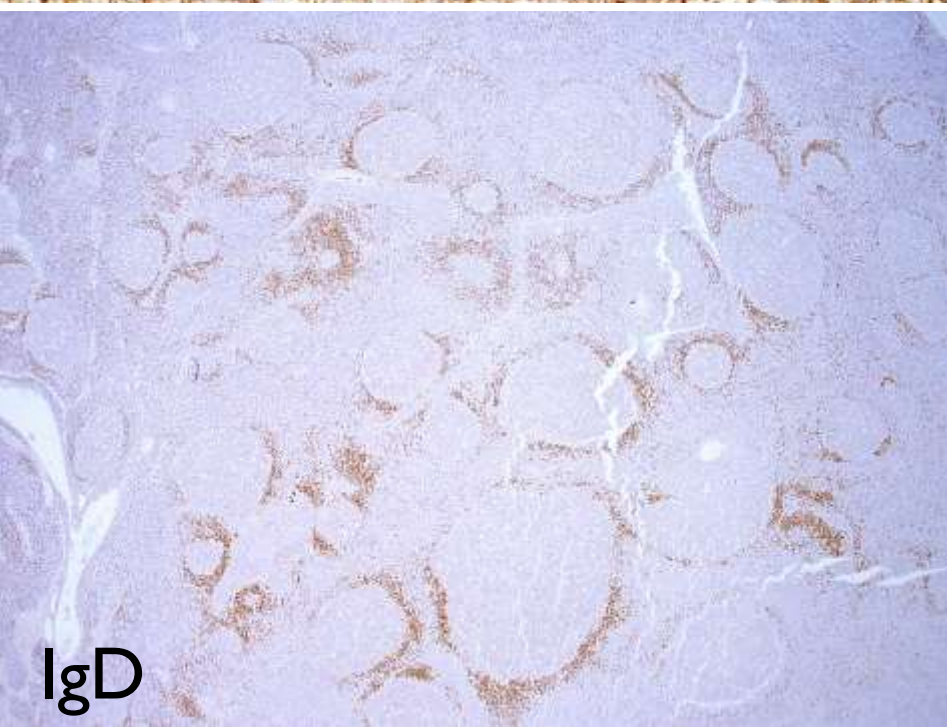
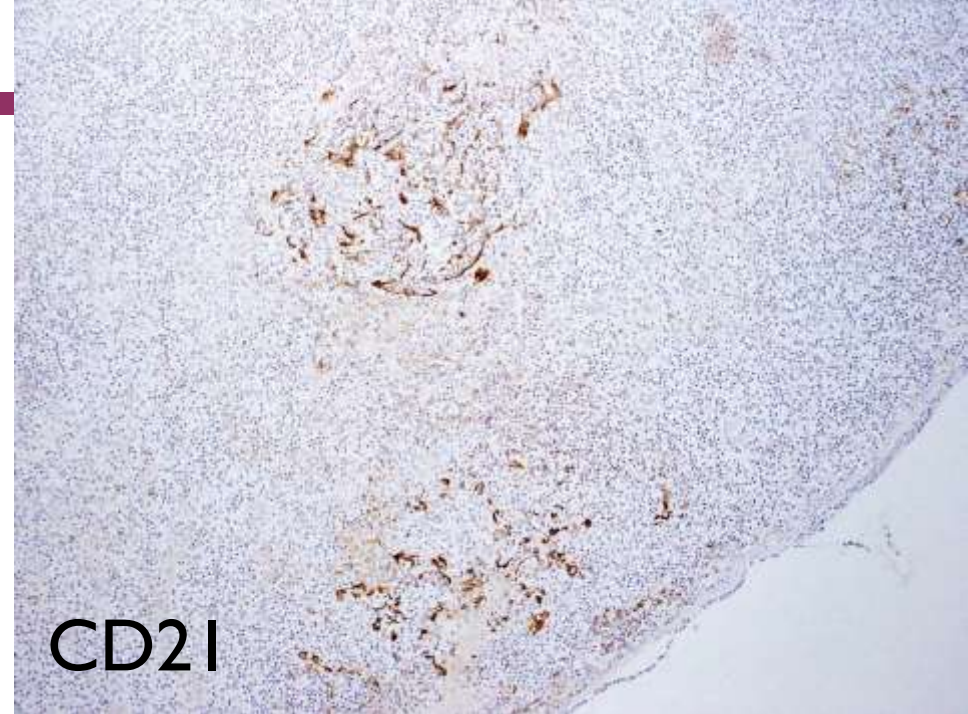
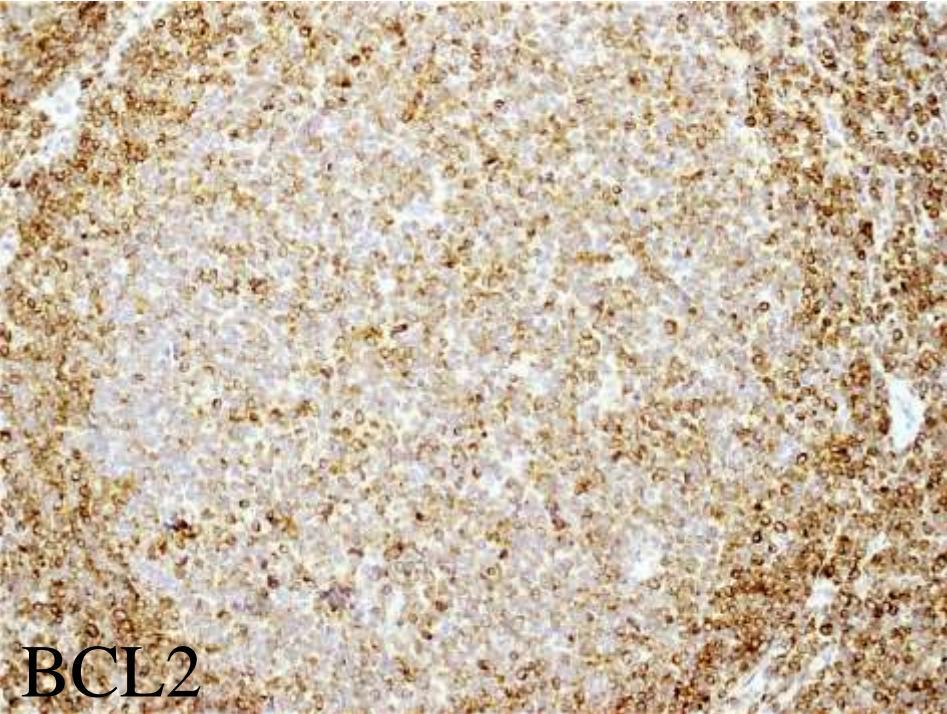


Hyperplastic
follicles

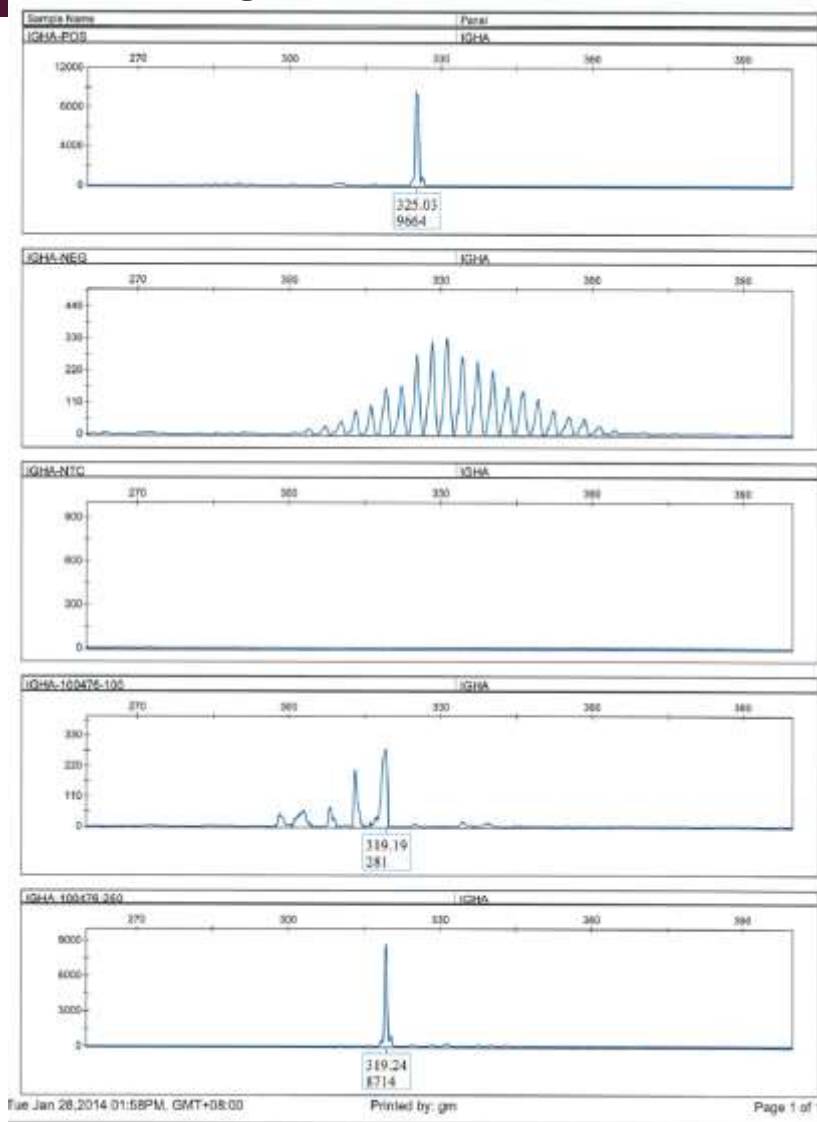




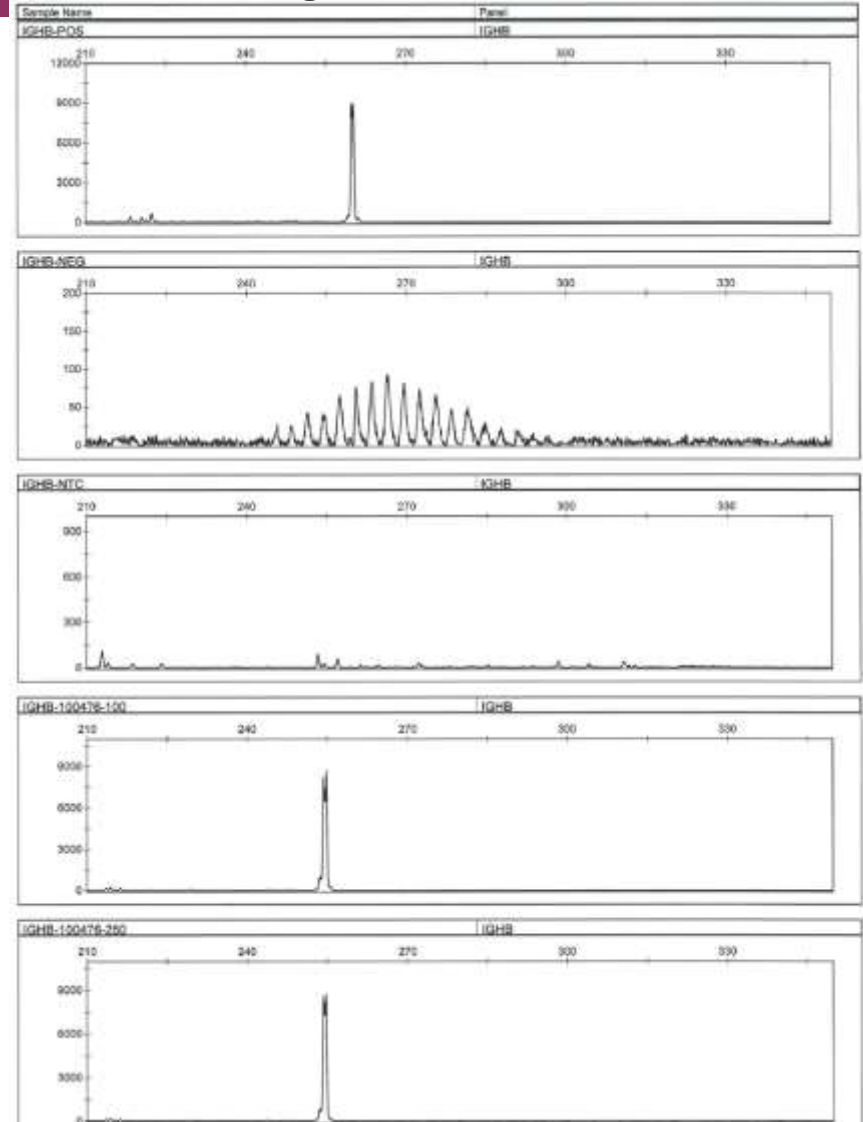




IgH Tube A



IgH Tube B



Monoclonal rearrangement of IgH Tube A, B, C, D

CASE 1 – SUMMARY

■ Pathology

- Lymph nodes partially effaced
- Many large hyperplastic follicles
- Expansion of interfollicular areas by a polymorphous population
 - small lymphocytes,
 - variable number of monocytoïd cells, scattered eosinophils,
 - few scattered centroblasts.
- Features of progressive transformation of germinal centres (PTGC) not prominent.

CASE 1 - SUMMARY

■ IHC

- The follicles
 - CD20+, Bcl2+, bcl6+ and CD10+.
 - disrupted CD21+ FDC meshworks, suggestive of follicular colonization.
 - Proliferative index high with loss of polarity.
- Interfollicular tumour cells:
 - CD20+, bcl2 +, CD10-, bcl6-, CD5-, CD43-.
 - Proliferation index is low.

CASE 1 - SUMMARY

- Cytogenetics:
 - BM aspirate: 46XY normal male
 - IgH PCR performed on Apr 2010 lymph node biopsy showed monoclonal rearrangement using Biomed primers

Diagnosis: Pediatric nodal marginal zone lymphoma

PEDIATRIC NODAL MARGINAL ZONE LYMPHOMA

- M >> F
- Asymptomatic localized disease (head and neck)
- Histology
 - Hyperplastic follicles resembling progressive transformation of germinal centre (PTGC)
 - MZ pattern: Expansion of interfollicular region by B cells
- IHC
 - Same as adult NMZL (CD20+, CD10-, CD5-, BCL2+, CD43+)
 - IgD highlights PTGC-like changes

CASE 2

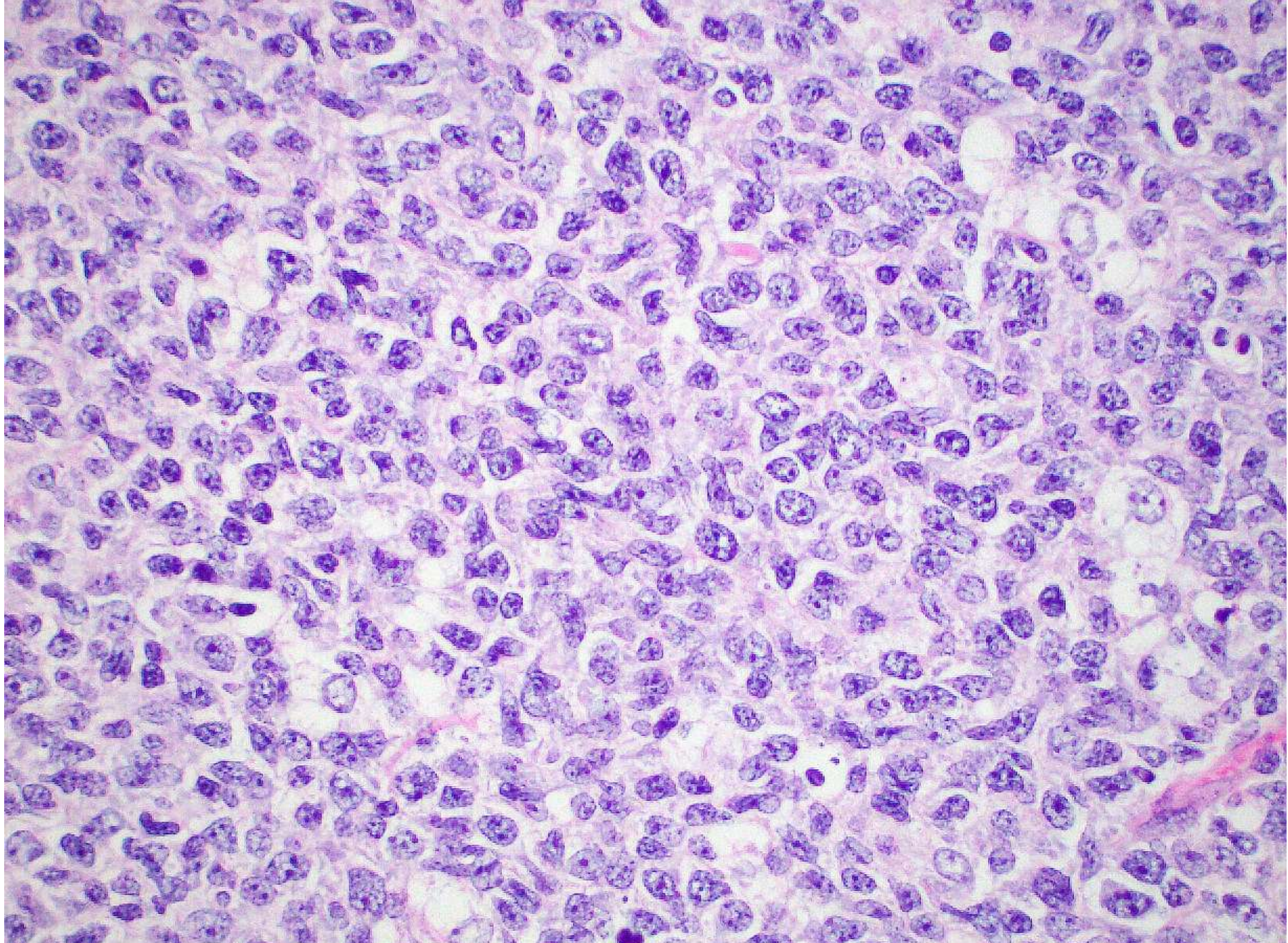
- 20 / M
- 2 cm submental lymph node

A histological slide of a lymph node stained with hematoxylin and eosin (H&E). The image shows a dense population of cells with a purple hue, characteristic of hematoxylin staining. There are several large, irregular, and somewhat amorphous structures scattered throughout the field, which are identified as follicles. These follicles are effacing the normal architecture of the lymph node. The overall appearance is that of a lymphoproliferative disorder, such as a type of lymphoma.

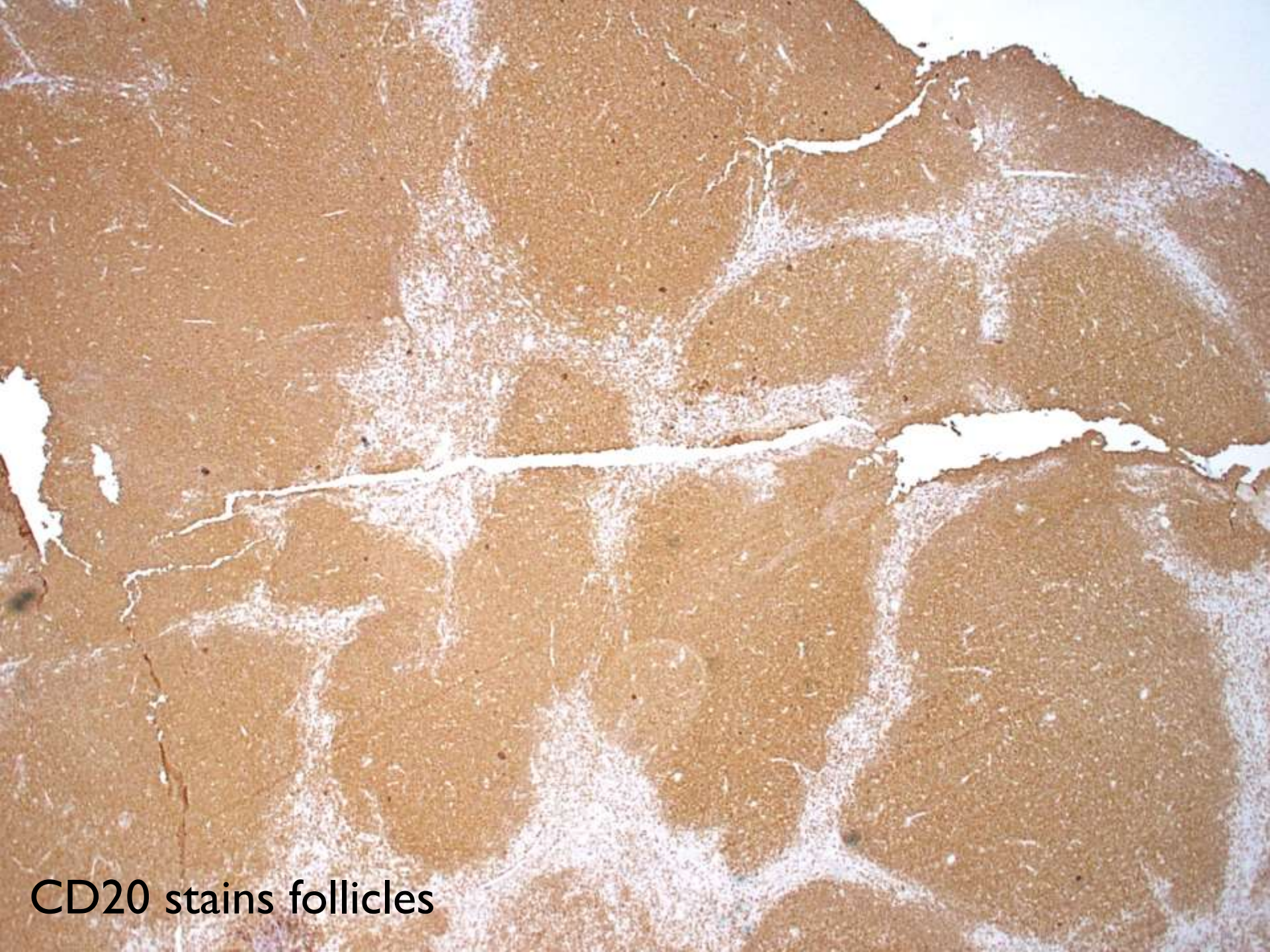Large irregular follicles effacing lymph node

A high-magnification histological micrograph of a tissue section stained with hematoxylin and eosin (H&E). The image displays numerous follicles, which are clusters of cells. These follicles exhibit a 'starry sky' appearance, characterized by a dense population of small, dark-staining nuclei (lymphocytes) interspersed with larger, pale-staining cells (likely macrophages or plasma cells). The overall texture is highly cellular and disorganized, consistent with the description of 'hyperplastic' follicles. The background is a dense, purple-stained matrix of cells.

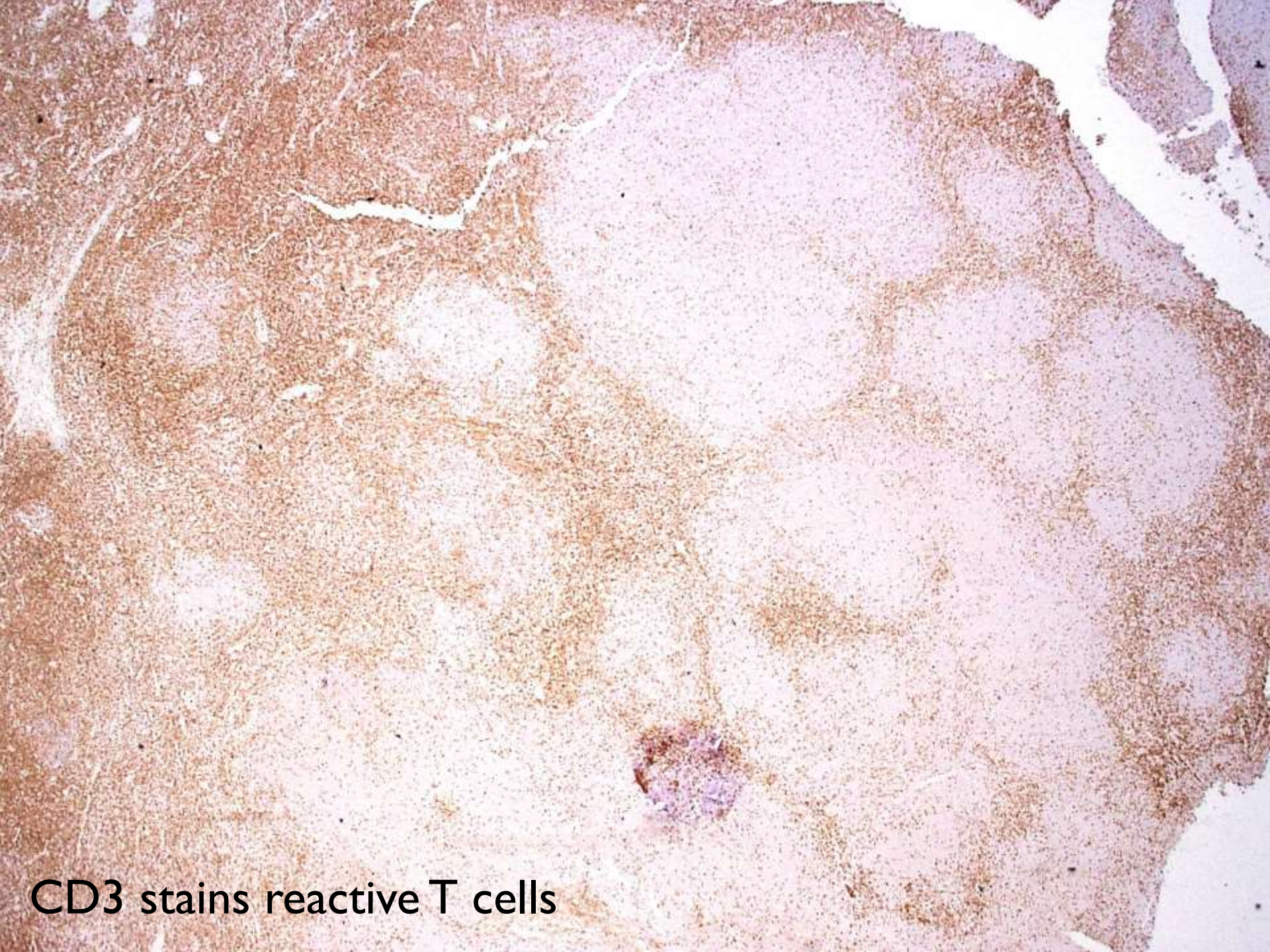
'Hyperplastic' looking follicles with starry sky



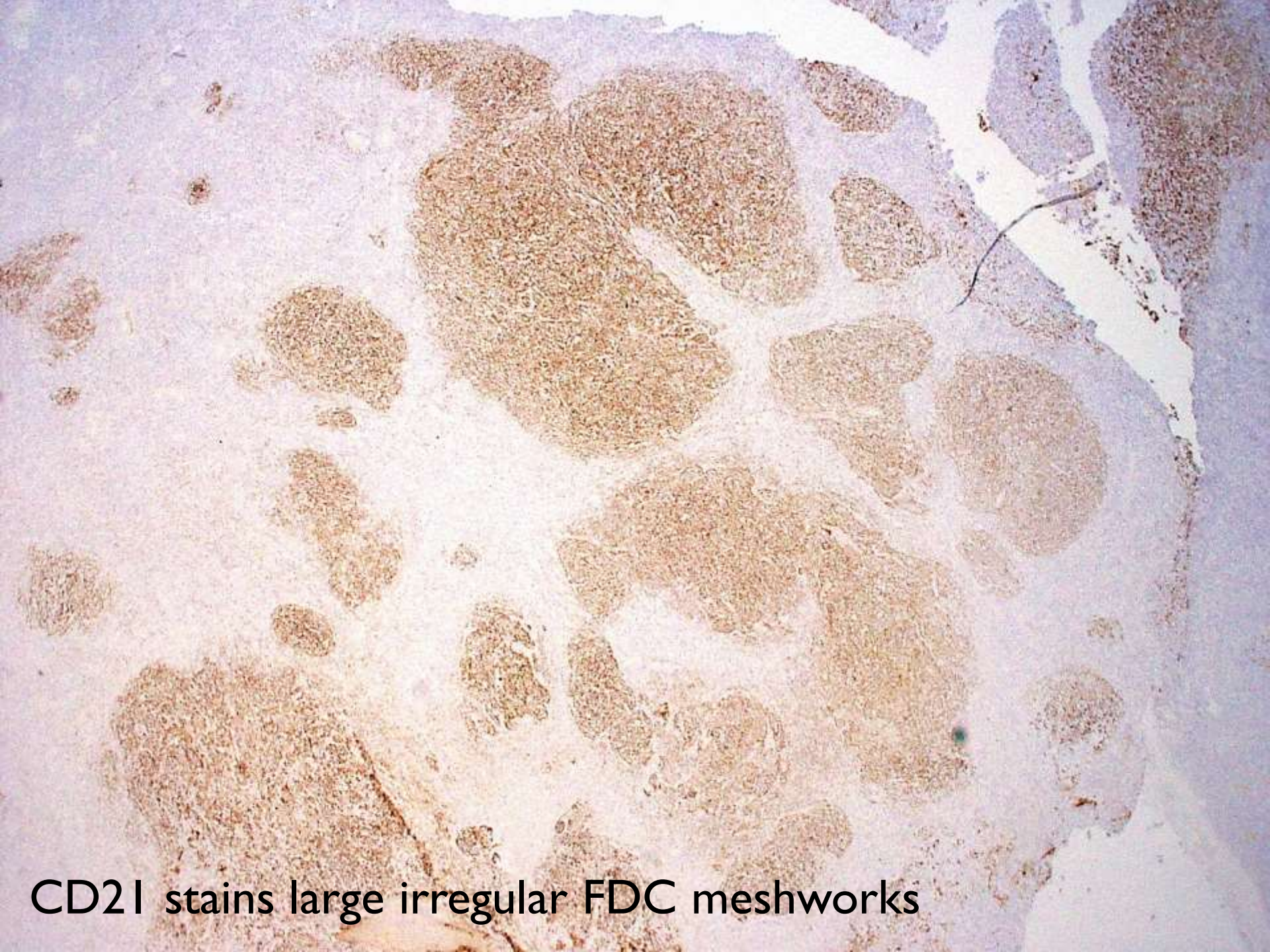
Follicular cells are intermediate in size and blastoid



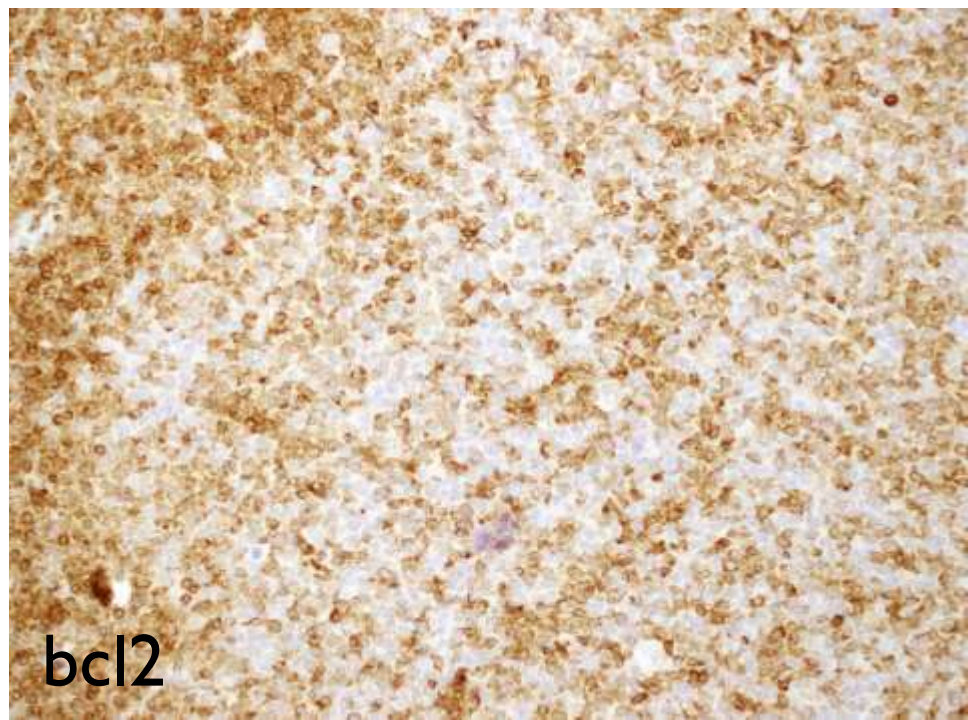
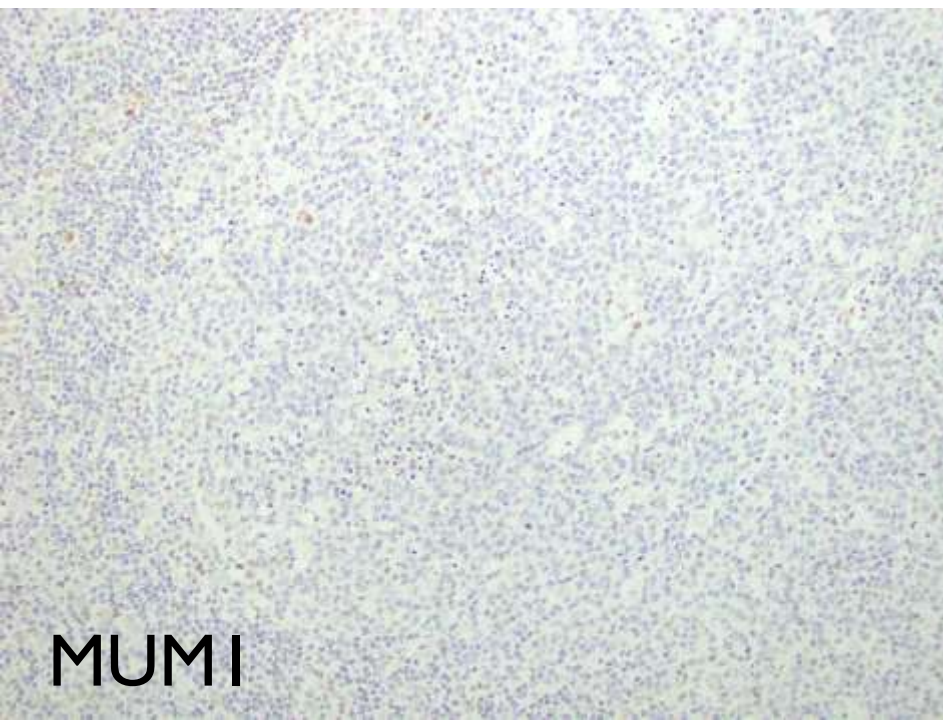
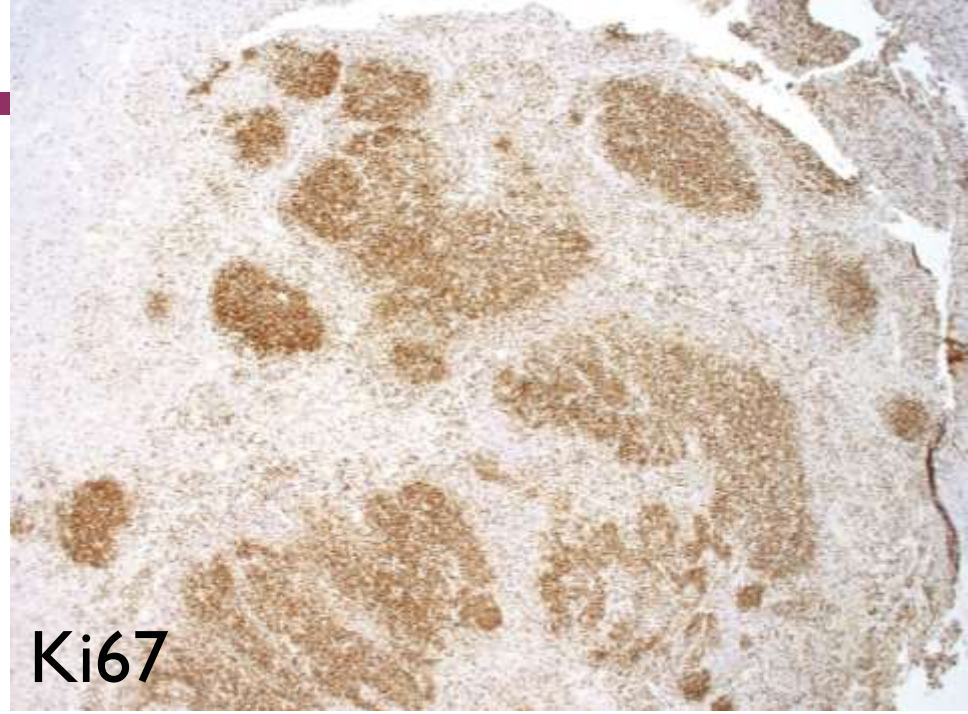
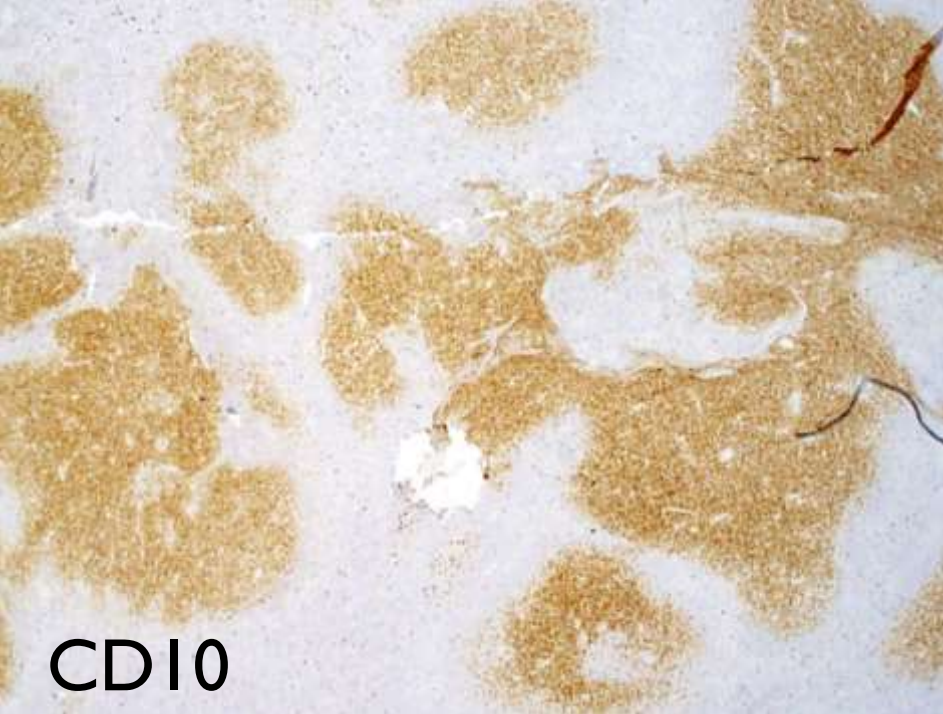
CD20 stains follicles



CD3 stains reactive T cells



CD21 stains large irregular FDC meshworks



CASE 2 -SUMMARY

- Young, isolated submental LN
 - Pathology
 - Partial effacement of LN
 - Large follicles lacking polarity
 - No diffuse areas
 - Follicles monotonous with intermediate, blastoid cells
 - Follicles: CD20+, CD10+, focal BCL2+, high ki67, MUM1-
 - FISH for t(14;18) negative
 - IgH PCR: Monoclonal
 - BM and cytogenetics: negative
- What is the diagnosis?
 - A. Reactive follicular hyperplasia
 - B. Pediatric nodal marginal zone lymphoma
 - C. Follicular lymphoma, high grade
 - D. Pediatric-type follicular lymphoma

CASE 2 -SUMMARY

- Young, isolated submental LN
- Pathology
 - Partial effacement of LN
 - Large follicles lacking polarity
 - No diffuse areas
 - Follicles monotonous with intermediate, blastoid cells
 - Follicles: CD20+, CD10+, focal BCL2+, high ki67, MUM1-
- FISH for t(14;18) negative
- IgH PCR: Monoclonal
- BM and cytogenetics: negative

■ What is the diagnosis?

- A. Reactive follicular hyperplasia
- B. Pediatric nodal marginal zone lymphoma
- C. Follicular lymphoma, high grade
- D. **Pediatric-type follicular lymphoma**

| | Pediatric-type FL (does not include testicular FL or FL with IRF4 rearrangement) |
|------------|--|
| Morphology | <ol style="list-style-type: none"> 1. Effacement of architecture (at least partial) 2. Pure follicular growth, no diffuse pattern 3. Expansile follicles 4. Blastoid / intermediate cells (not CC). Grading not needed |
| IHC | <ul style="list-style-type: none"> - CD10+, BCL6+ - BCL2 negative or weak - Ki67 high(>30%) - MUM1 (IRF4) negative |
| Genomics | <ul style="list-style-type: none"> - No BCL2 / BCL6 / IRF4 rearrangement - No BCL2 amplification |
| Clinical | <ul style="list-style-type: none"> - Nodal disease - Stage 1-2 - Less than 40 yrs - Marked male predominance |

Red: required for diagnosis

| | Pediatric-type FL (does not include testicular FL or FL with IRF4 rearrangement) |
|------------|--|
| Morphology | <ol style="list-style-type: none"> 1. Effacement of architecture (at least partial) 2. Pure follicular growth, no diffuse pattern 3. Expansile follicles 4. Blastoid / intermediate cells (not CC). Grading not needed |
| IHC | <ul style="list-style-type: none"> - CD10+, BCL6+ - BCL2 negative or weak - Ki67 high(>30%) - MUM1 (IRF4) negative |
| Genomics | <ul style="list-style-type: none"> - No BCL2 / BCL6 / IRF4 rearrangement - No BCL2 amplification |
| Clinical | <ul style="list-style-type: none"> - Nodal disease - Stage 1-2 - Less than 40 yrs - Marked male predominance |

Red: required for diagnosis

| | Pediatric-type FL (does not include testicular FL or FL with IRF4 rearrangement) |
|------------|--|
| Morphology | <ol style="list-style-type: none"> 1. Effacement of architecture (at least partial) 2. Pure follicular growth, no diffuse pattern 3. Expansile follicles 4. Blastoid / intermediate cells (not CC). Grading not needed |
| IHC | <ul style="list-style-type: none"> - CD10+, BCL6+ - BCL2 negative or weak - Ki67 high(>30%) - MUM1 (IRF4) negative |
| Genomics | <ul style="list-style-type: none"> - No BCL2 / BCL6 / IRF4 rearrangement - No BCL2 amplification |
| Clinical | <ul style="list-style-type: none"> - Nodal disease - Stage 1-2 - Less than 40 yrs - Marked male predominance |

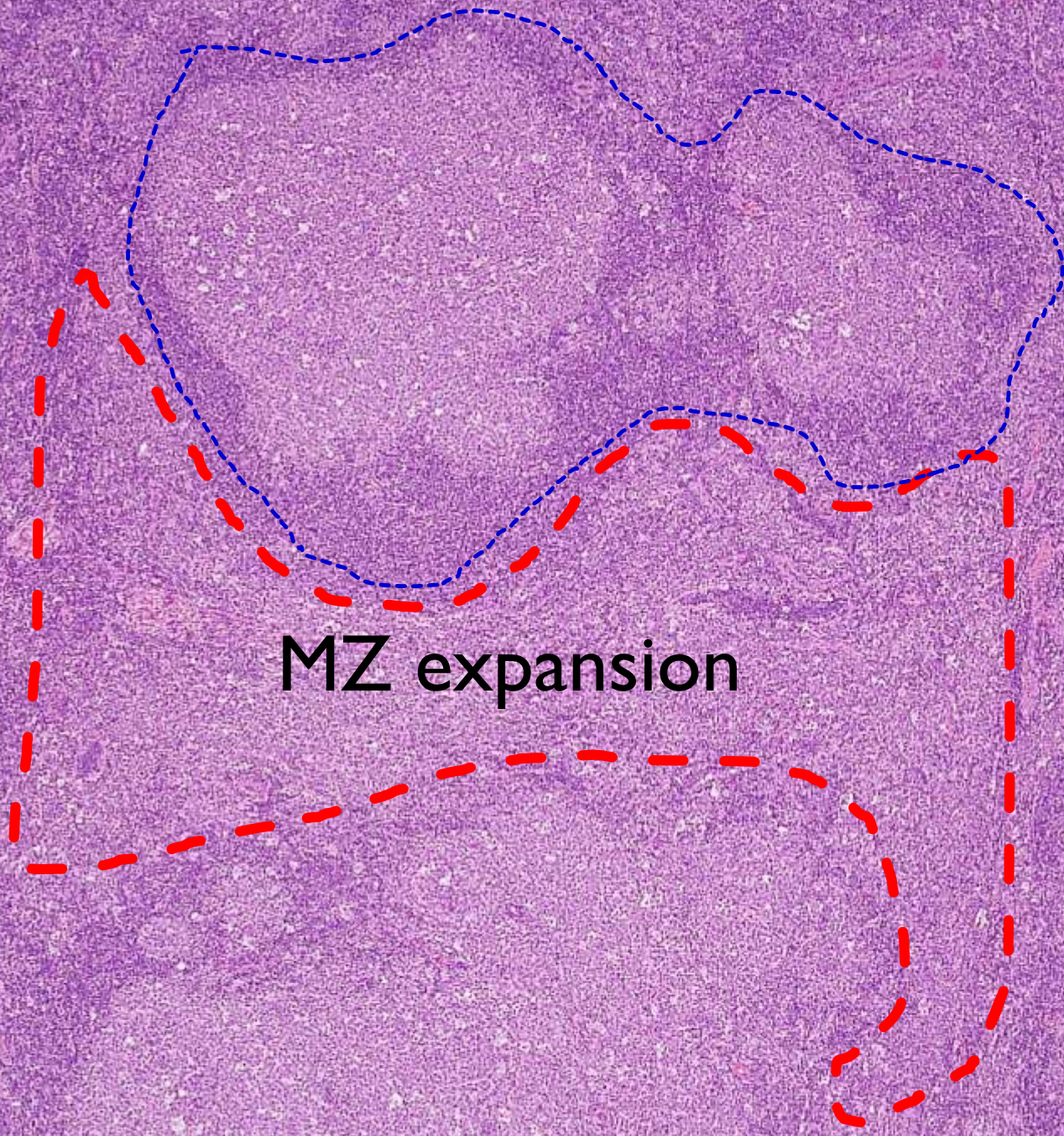
Red: required for diagnosis

| | Pediatric-type FL (does not include testicular FL or FL with IRF4 rearrangement) |
|------------|--|
| Morphology | <ol style="list-style-type: none"> 1. Effacement of architecture (at least partial) 2. Pure follicular growth, no diffuse pattern 3. Expansile follicles 4. Blastoid / intermediate cells (not CC). Grading not needed |
| IHC | <ul style="list-style-type: none"> - CD10+, BCL6+ - BCL2 negative for weak - Ki67 high(>30%) - MUM1 (IRF4) negative |
| Genomics | <ul style="list-style-type: none"> - No BCL2 / BCL6 / IRF4 rearrangement - No BCL2 amplification |
| Clinical | <ul style="list-style-type: none"> - Nodal disease - Stage 1-2 - Less than 40 yrs - Marked male predominance |

Red: required for diagnosis

| | Pediatric NMZL | Pediatric-type FL (nodal) | Testicular FL (variant of usual FL) | Usual FL |
|------------------------|-----------------------|----------------------------------|--|--|
| Median age | 17 | 14 | children | 24 |
| M:F | M>>F | M>>F | M >> F | F> M |
| Head/Neck Predilection | Y | Y | N | N |
| Behaviour | Indolent | Indolent, Stage I | Indolent, stage I | Stage 3/4, indolent, multiple relapses |

| | Pediatric NMZL | Pediatric-type FL (nodal) | Testicular FL (variant of usual FL) | Usual FL |
|---------------------------------------|-----------------------|----------------------------------|--|-----------------|
| PTGC-like changes (IgD+ mantle zones) | Yes | No | No | No |
| Hyperplastic follicles, starry sky | Yes | Yes (intermediate or blastoid) | No. Follicles high grade (3A) | No |
| Ki67 (%) | Variable | High | High | 25% |
| CD10 (%) | - | + | + | + |
| BCL2 | + (50%) | - | - | + |
| BCL2 translocation | Absent | Absent | Absent | present |
| Clonality | Monoclonal | Monoclonal | Monoclonal | Monoclonal |



MZ expansion

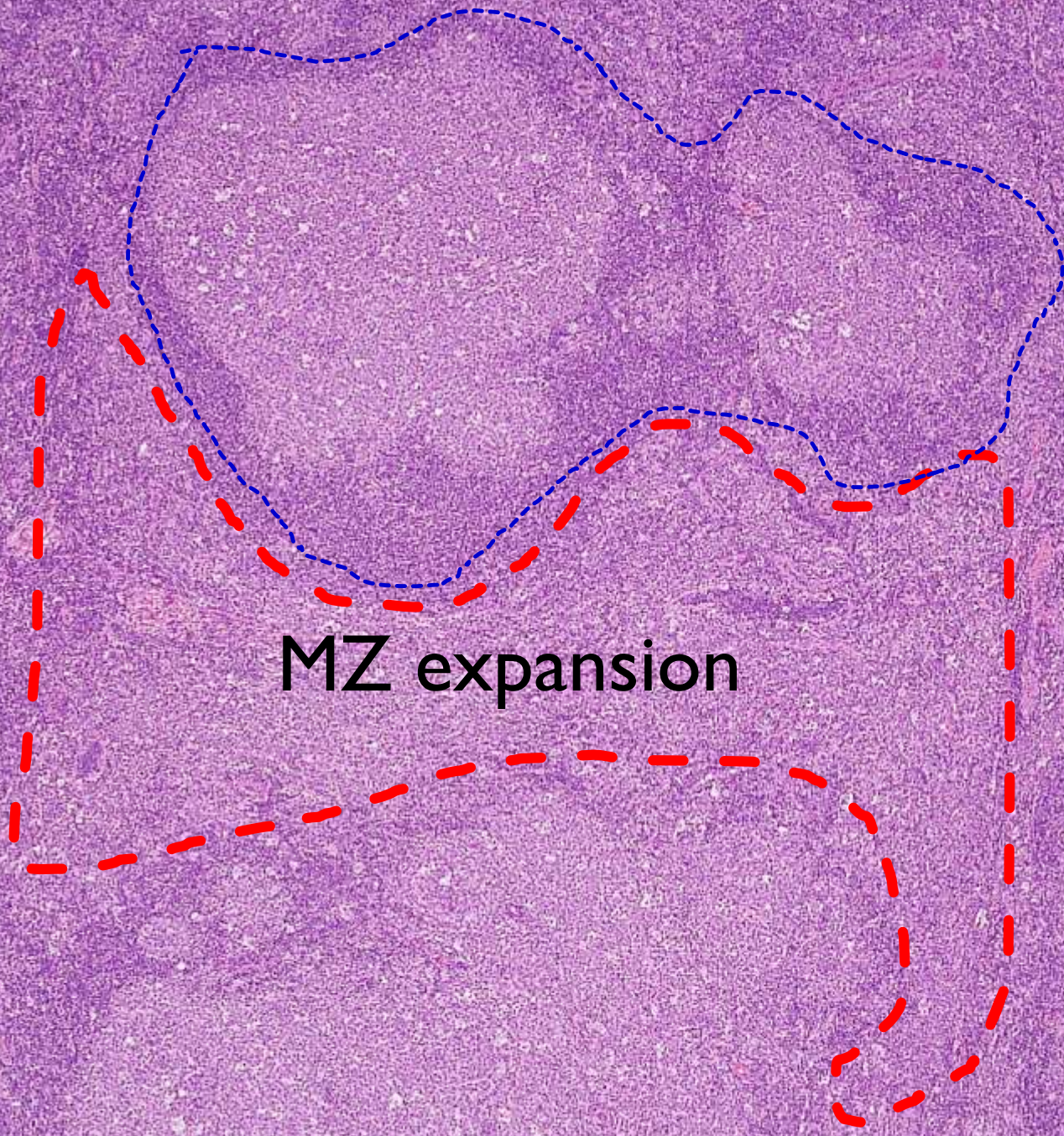
What is the most likely diagnosis based on this H&E?

A. Reactive hyperplasia

B. PTGC

C. Pediatric NMZL

D. Pediatric type FL



MZ expansion

What is the most likely diagnosis based on this H&E?

A. Reactive hyperplasia

B. PTGC

C. Pediatric NMZL

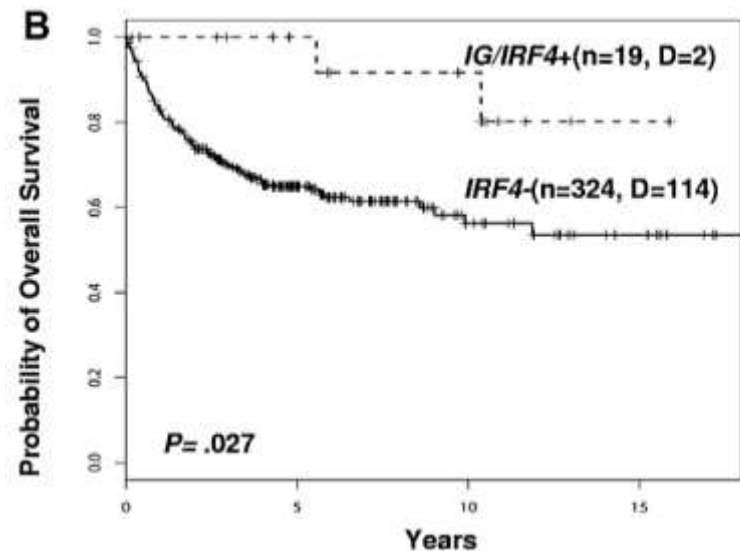
D. Pediatric type FL

LBCL WITH IRF4 REARRANGEMENT

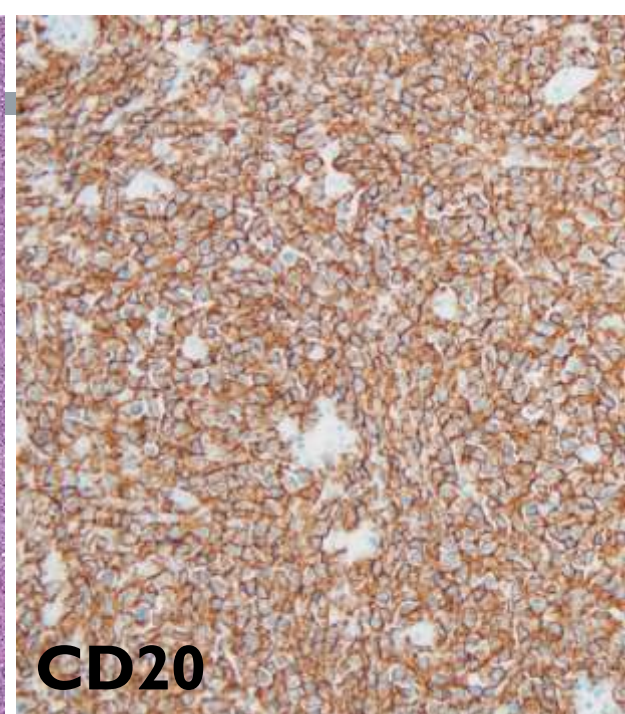
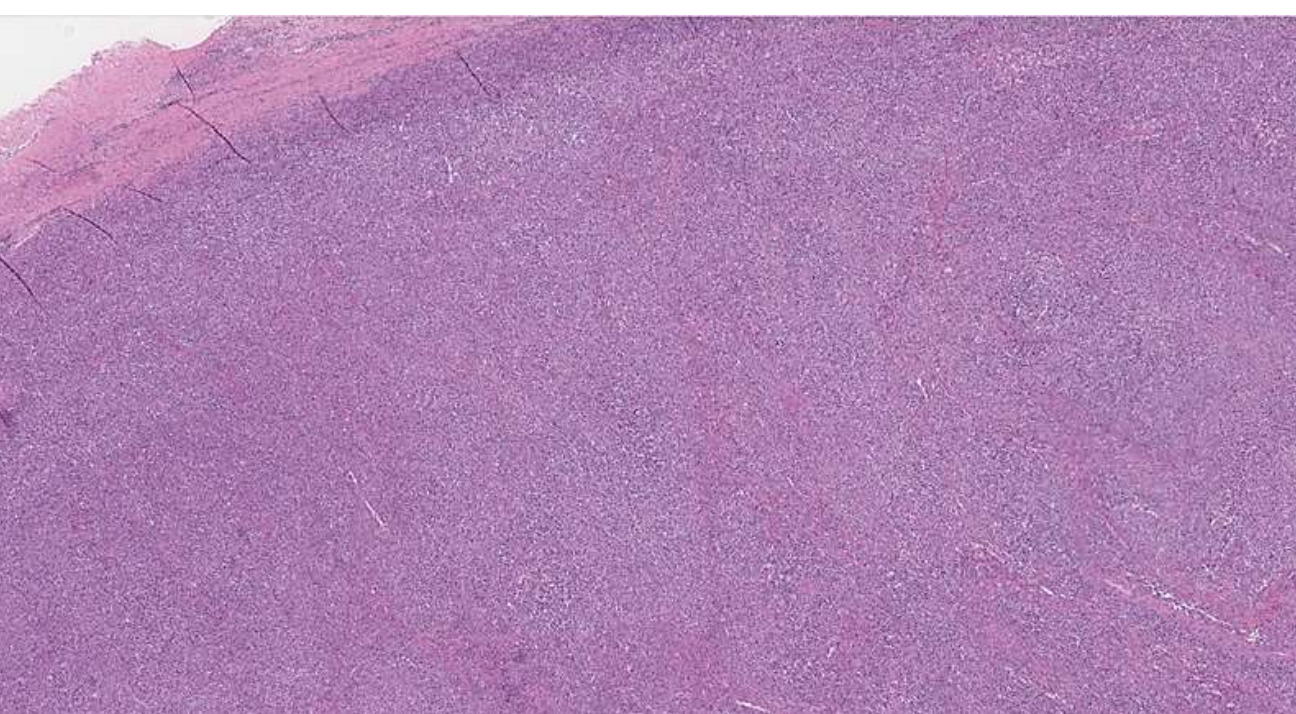
- New provisional entity
- Children and young adults
- Sites:
 - Waldeyer ring and/or cervical LN (typical), GIT (sometimes)
- Morphology: follicular/ diffuse (FL 3B or DLBCL)
- Positive IHC
 - IRF4 (MUM1), BCL6, high Ki67 (clue to diagnosis)
 - BCL2, CD10 (>50%)

LBCL WITH IRF4 REARRANGEMENT

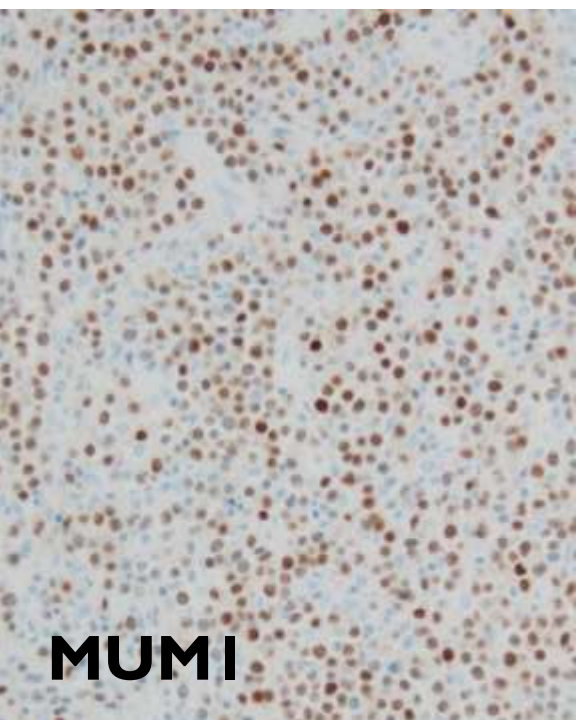
- Rearrangements:
 - Ig/IRF4 majority
 - BCL6 sometimes, No BCL2/MYC
- More aggressive than pFL but better than DLBCL NOS



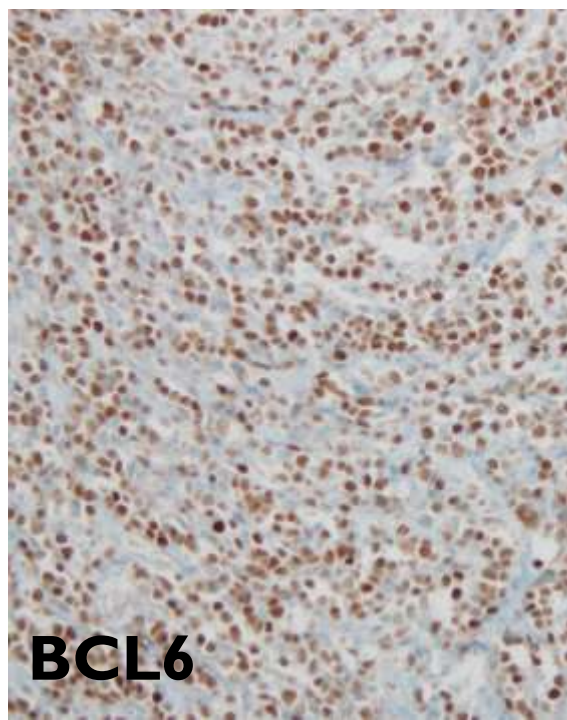
Kaplan-Meier curves show a better survival of IG/IRF4-positive cases ($P = .027$).



CD20

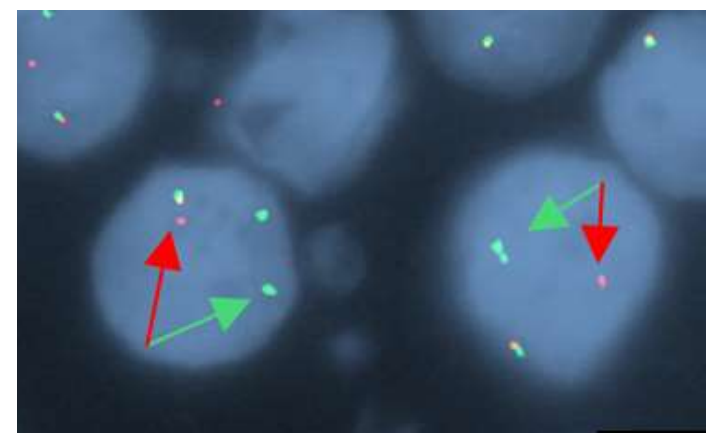


MUM1



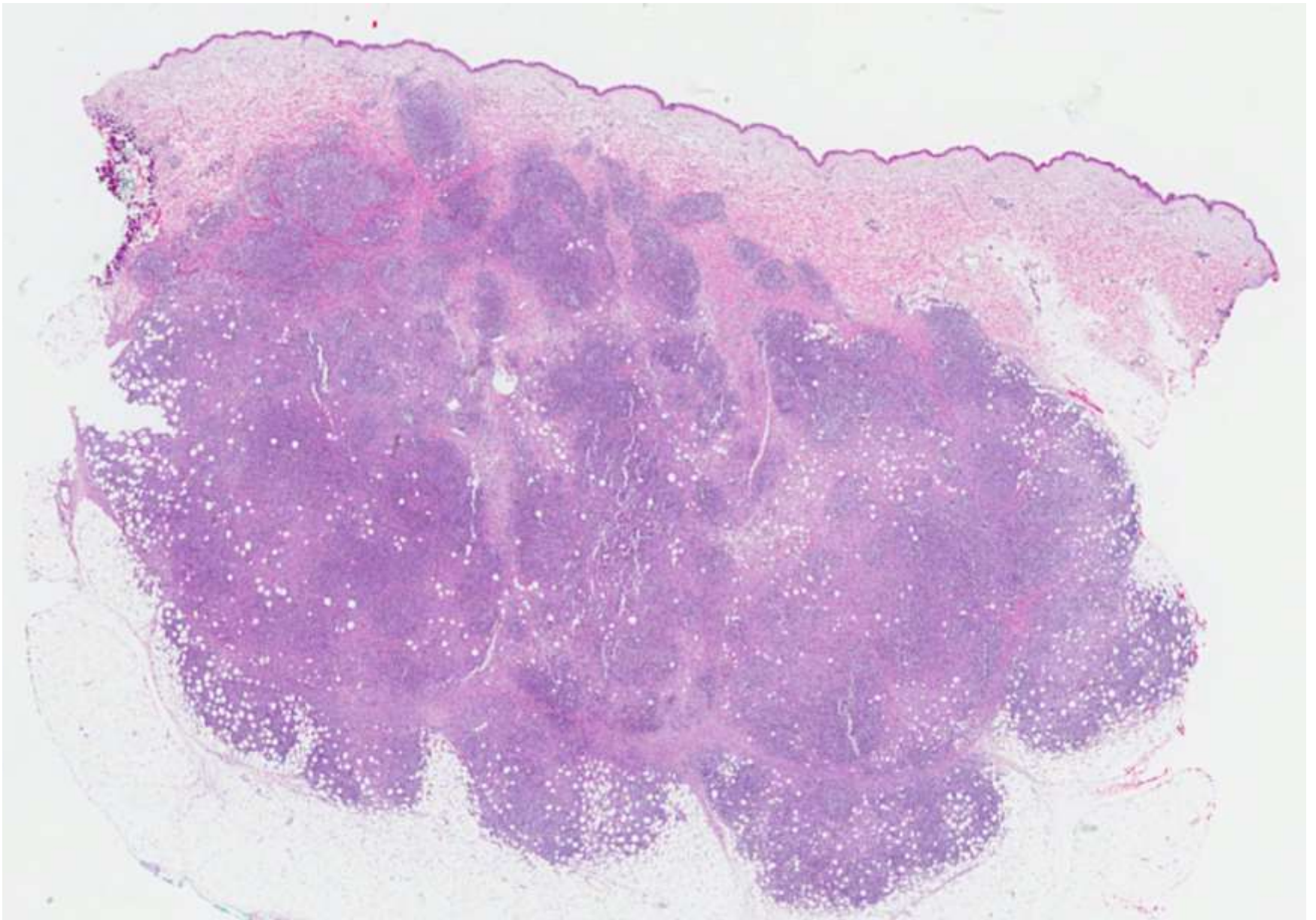
BCL6

FISH BAP:
5'IRF4(Red)/3'IRF4(Green)[6p25.3]

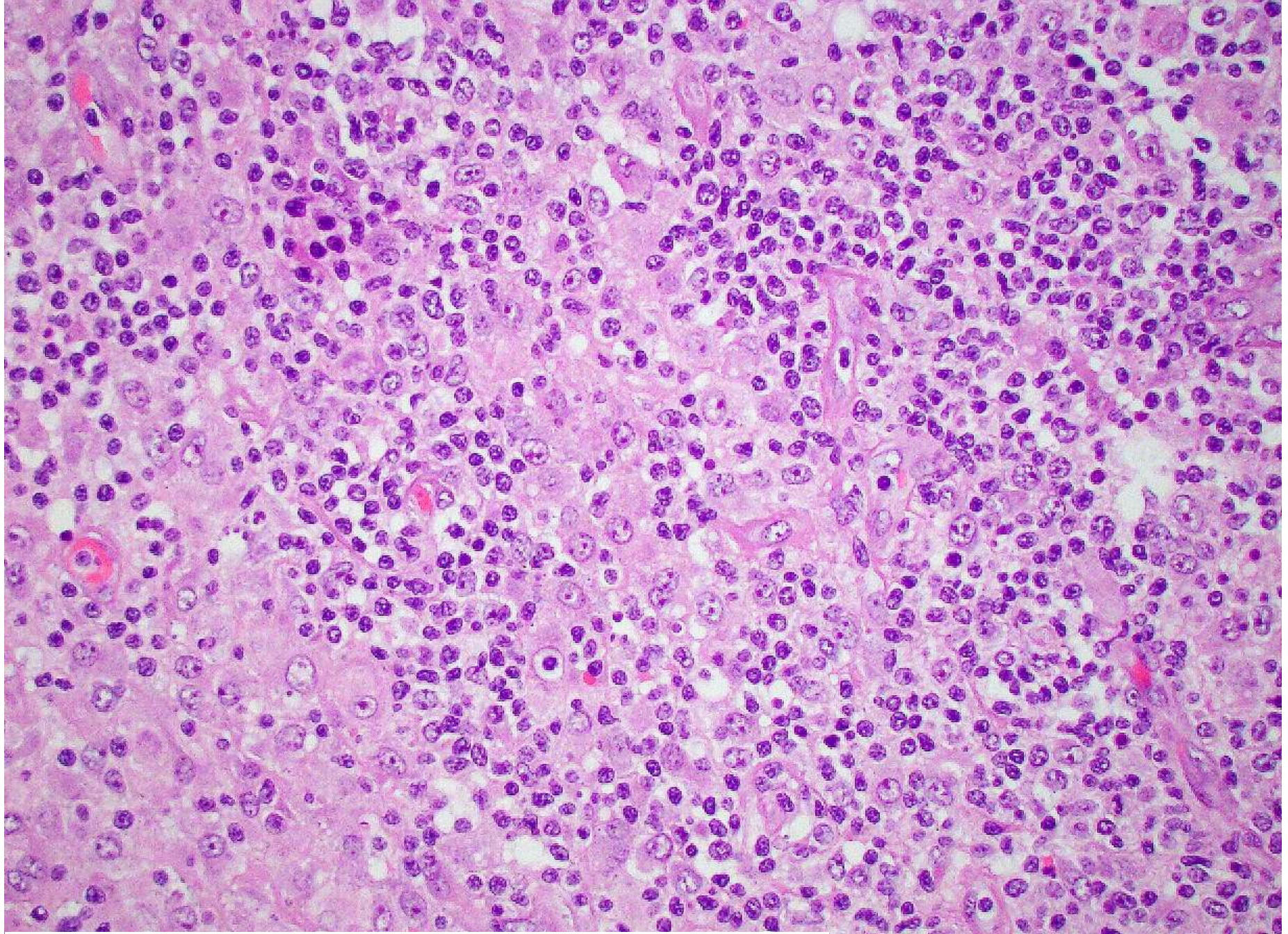


CASE 3

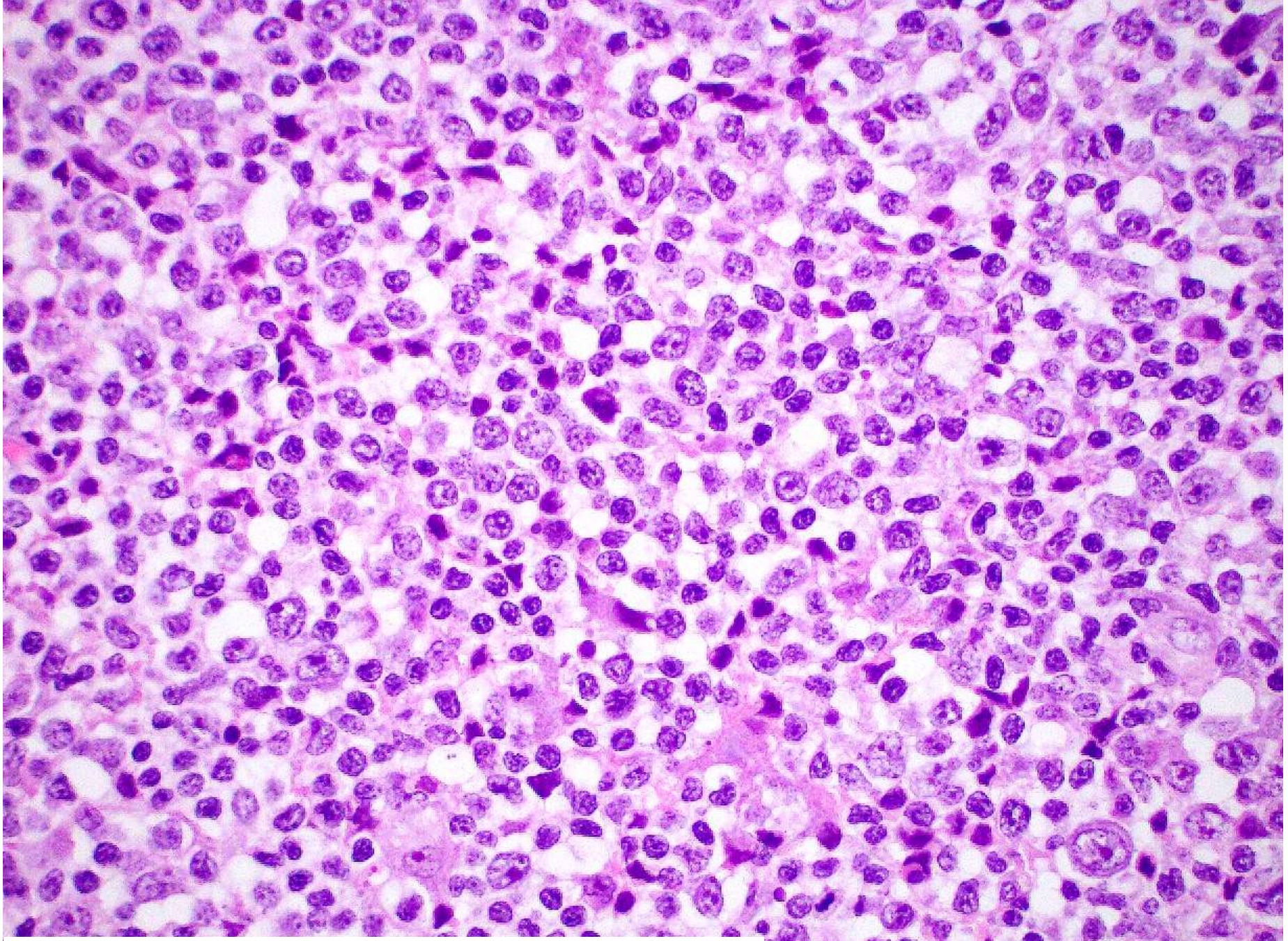
- 70 / F
- Aug 2011:
 - presented with left arm skin lump 1.5cm
 - CT scan: no LAD
 - BM negative
 - Treated with R-CHOP Nov 2011 to Feb 2012
- Aug 2012:
 - Developed Left mid calf skin lesion
 - Treated with rituximab and bendamustin, observed and followed up
- Sept 2013: PET scan: skin lesions resolved
- Mar 2017: alive, no new skin lesions



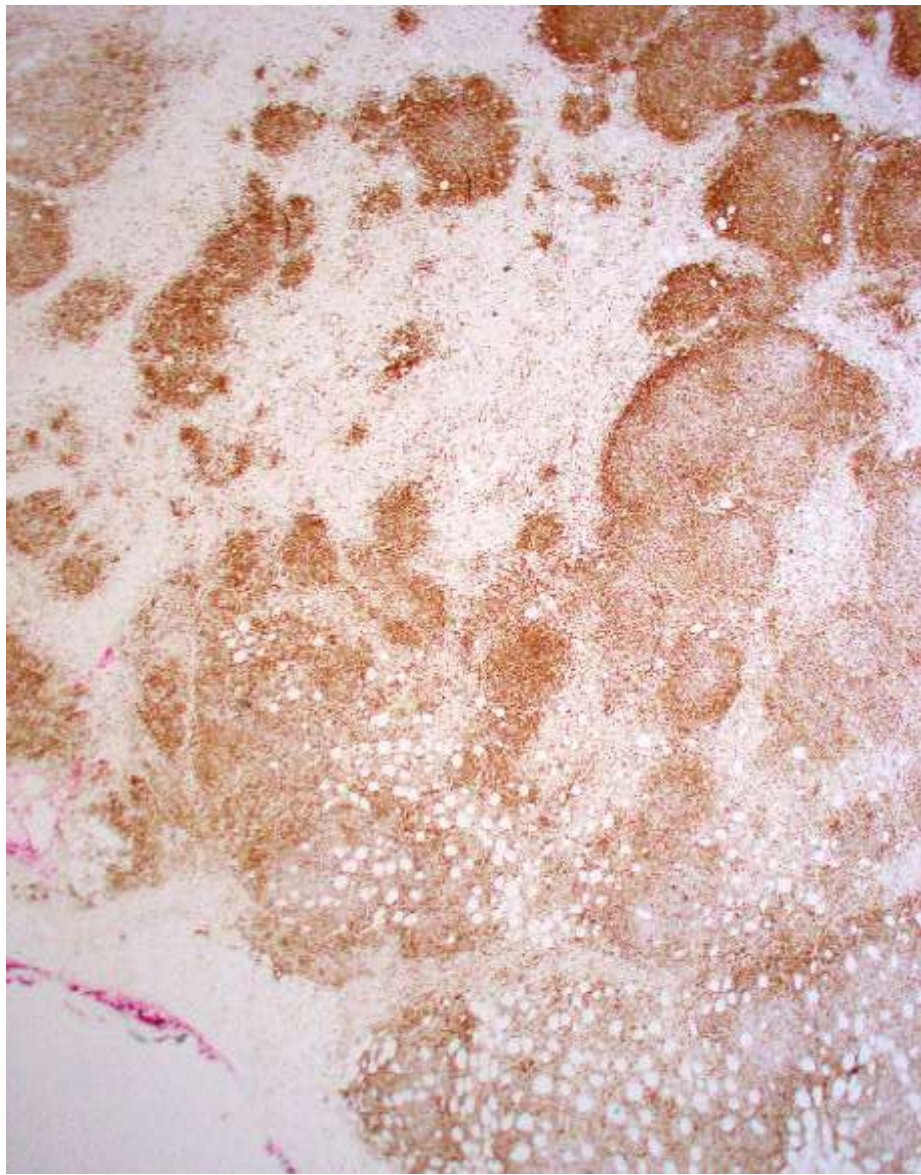
2011 Skin biopsy: well demarcated dense lymphoid proliferation



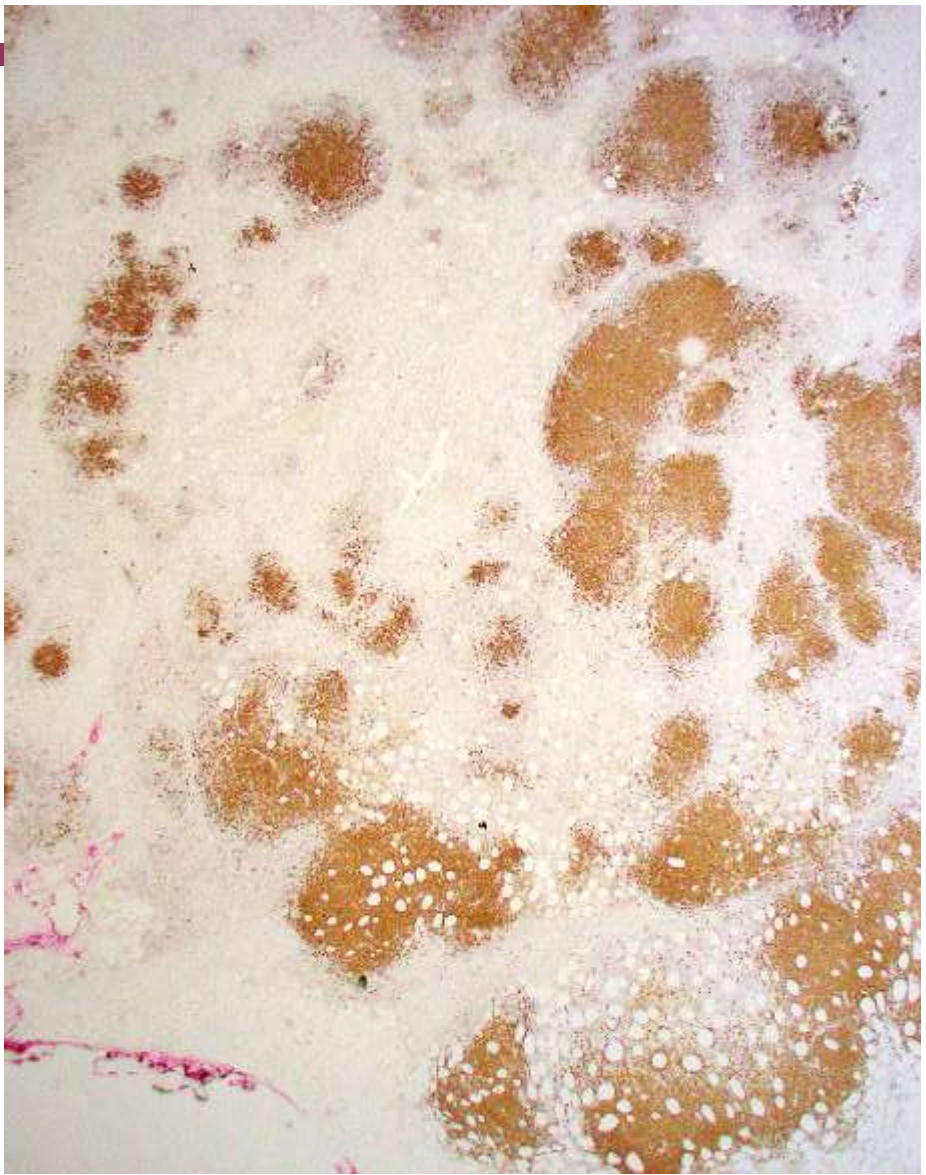Dense lymphoid polymorphous infiltrate



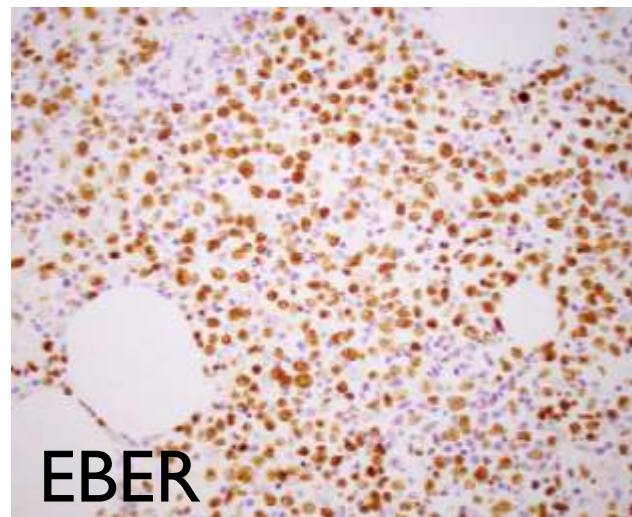
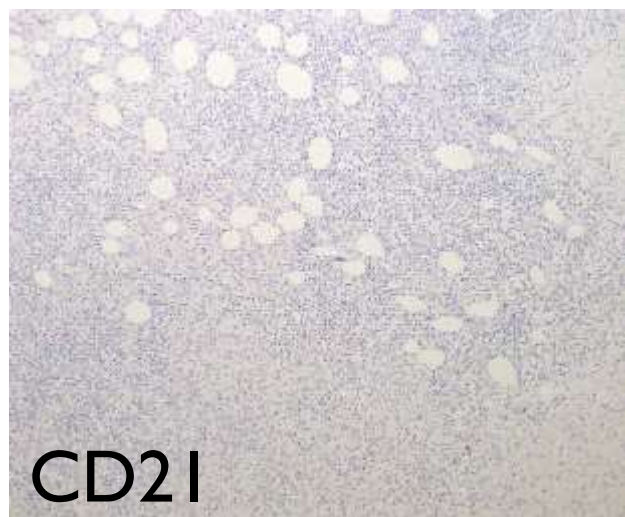
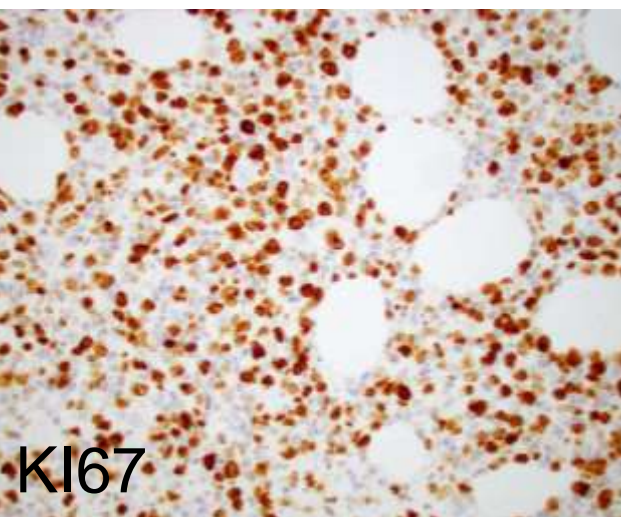
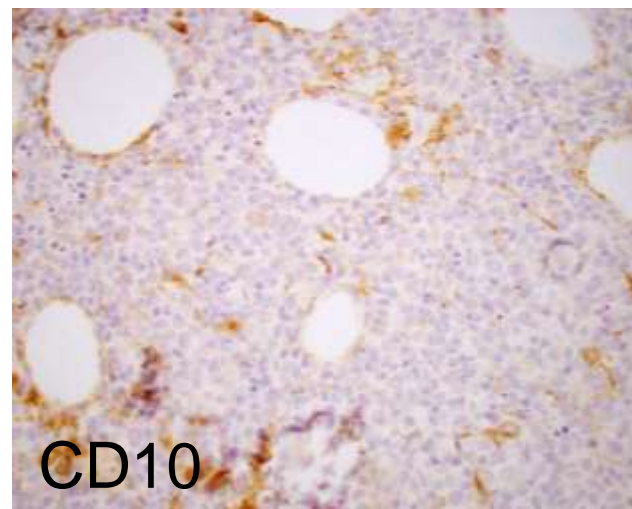
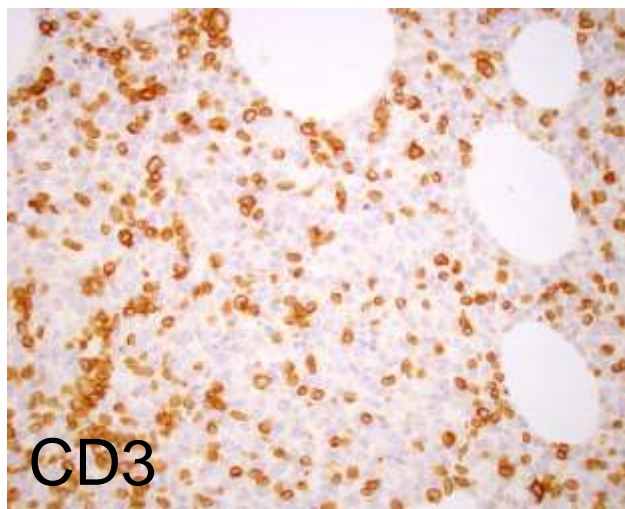
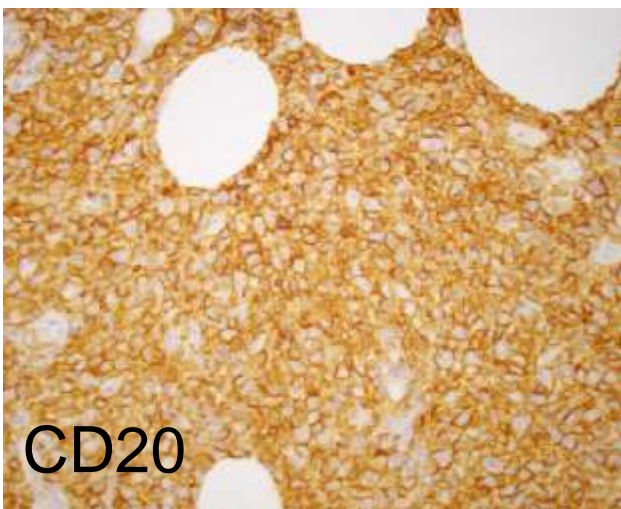
Some areas show sheets of large cells

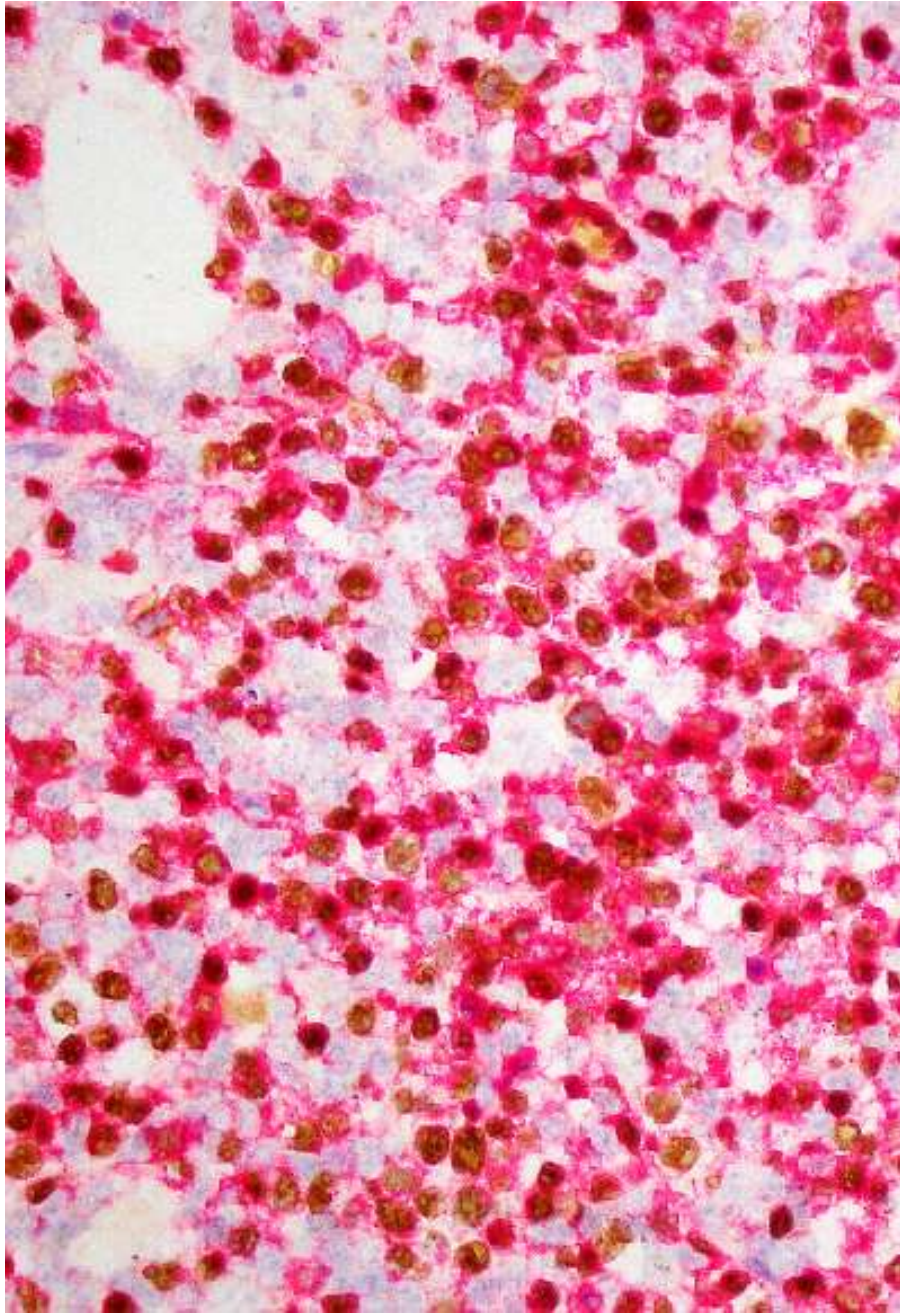


CD3

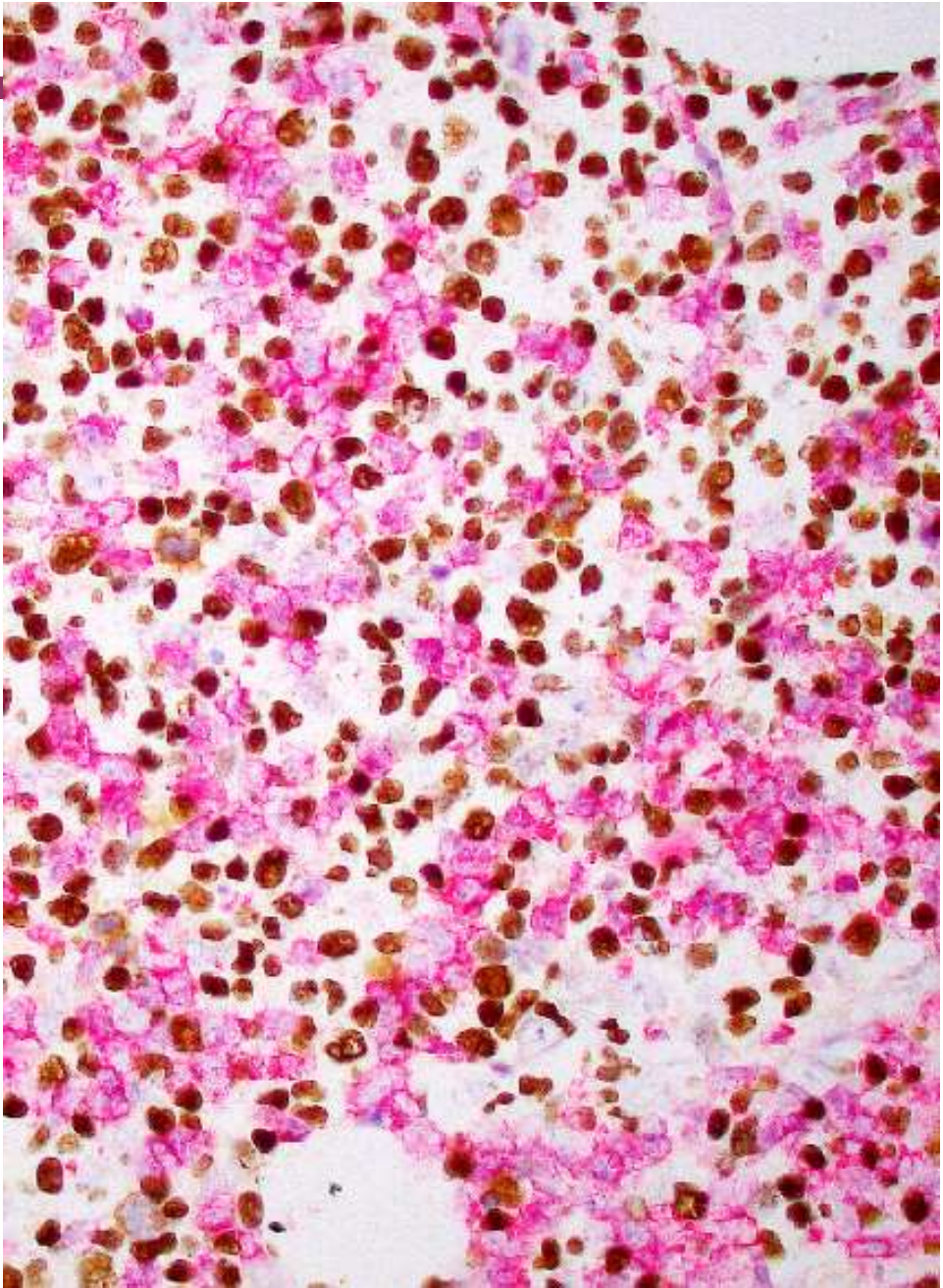


CD20





CD79A-EBER



CD3-EBER

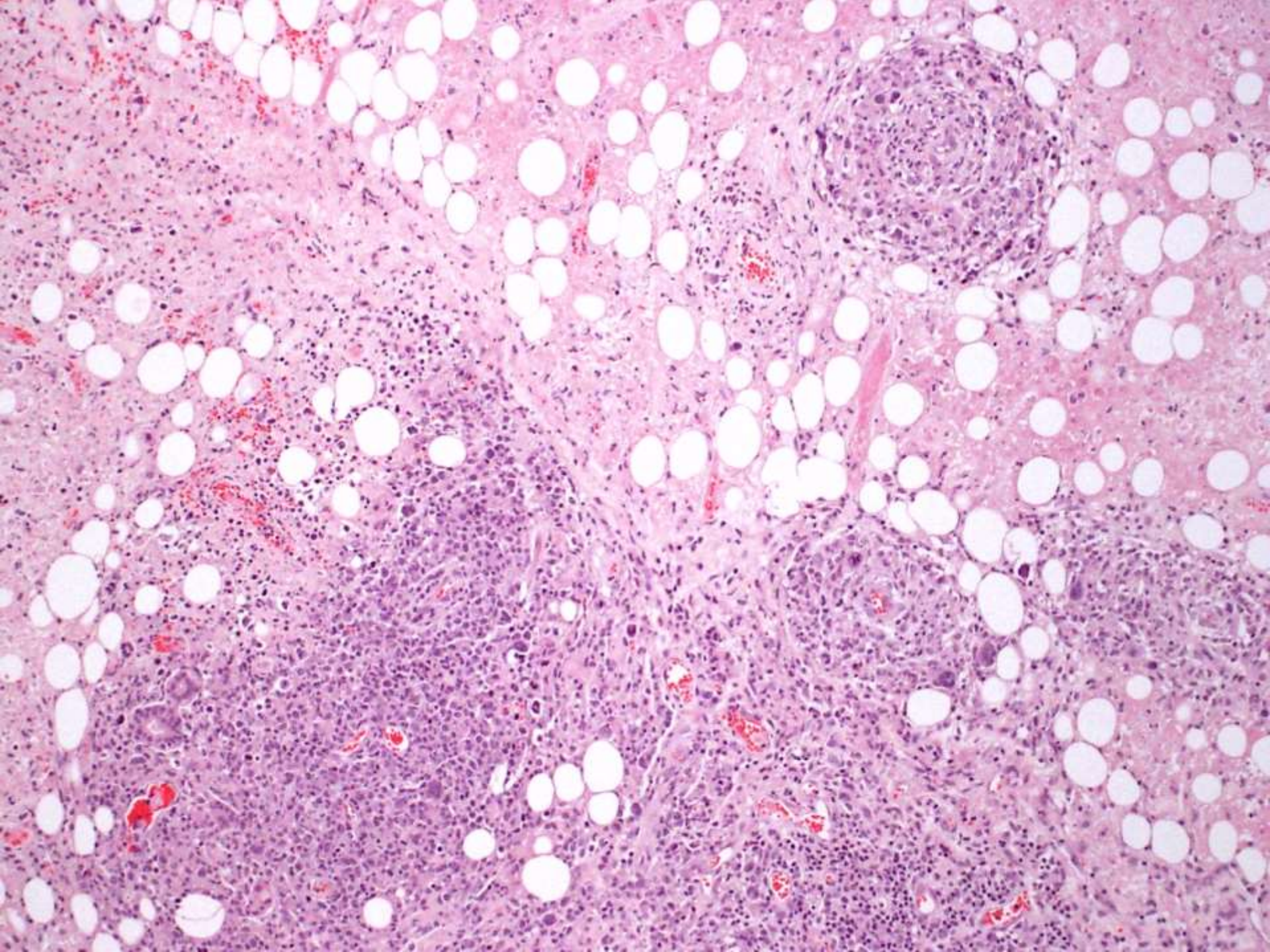
CASE 3

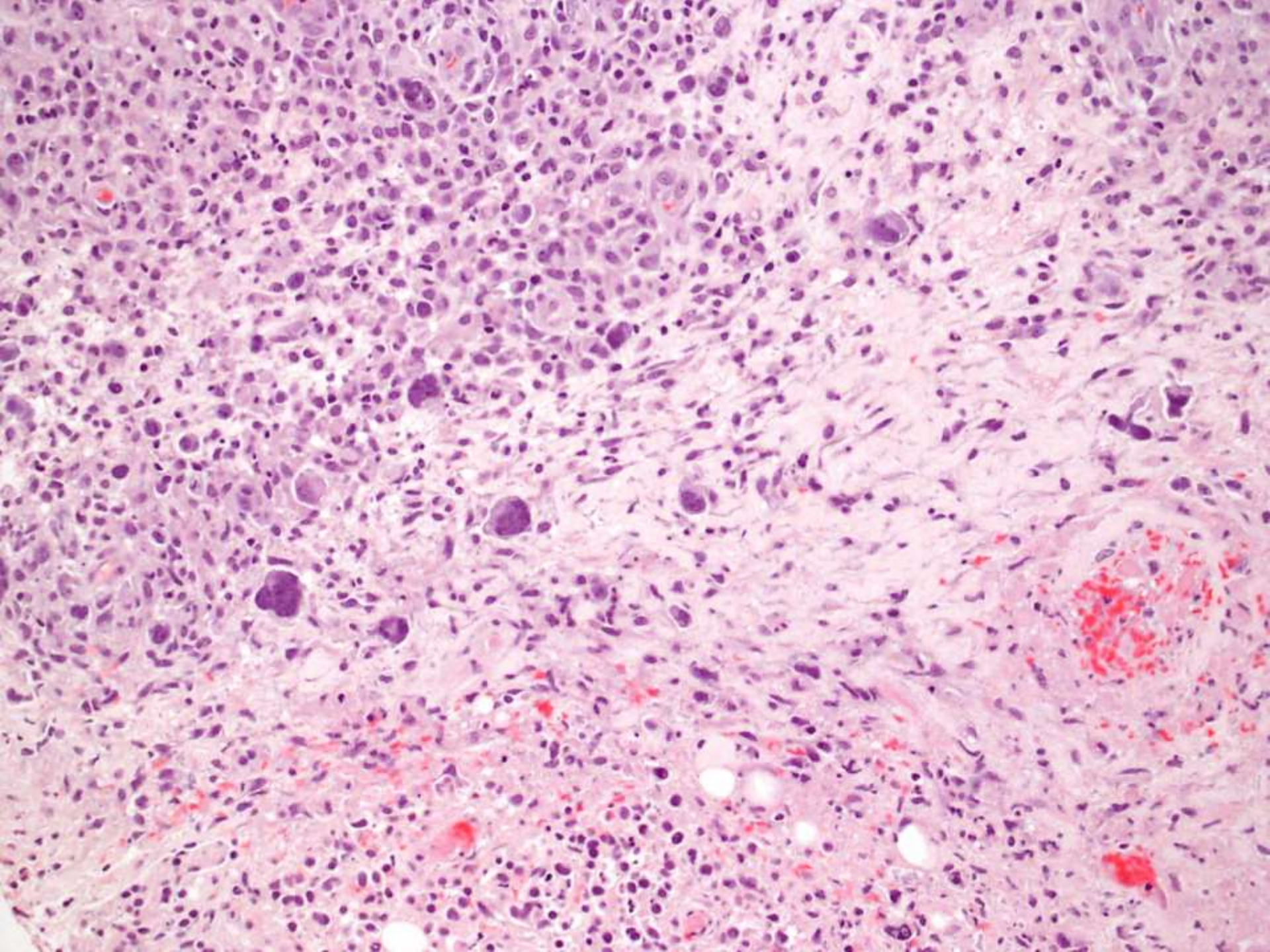
WHAT'S
YOUR
DIAGNOSIS?

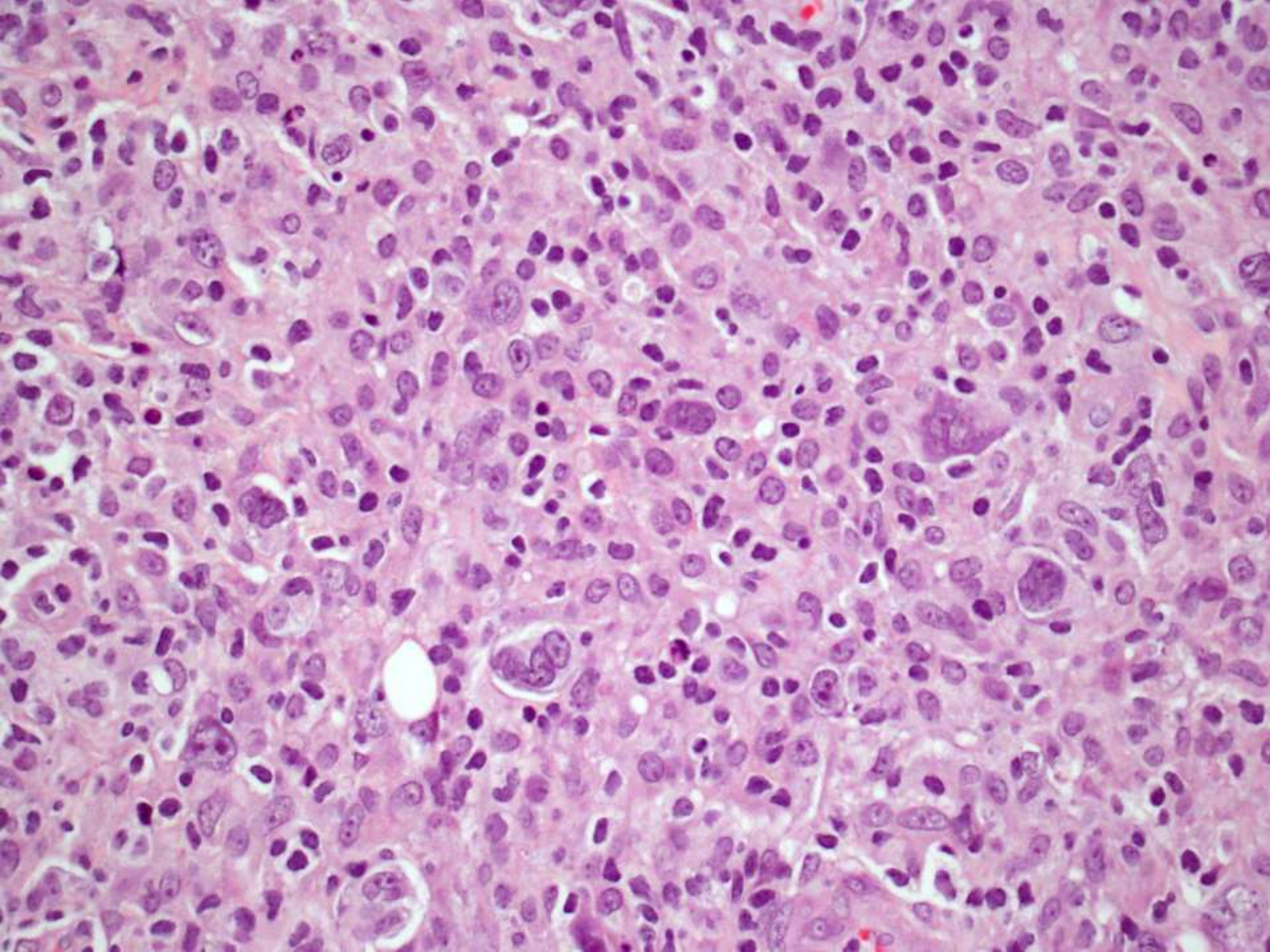
- A. Mucocutaneous Ulcer
- B. Diffuse large B cell lymphoma, EBV+
- C. Lymphomatoid granulomatosis
- D. Classical Hodgkin lymphoma

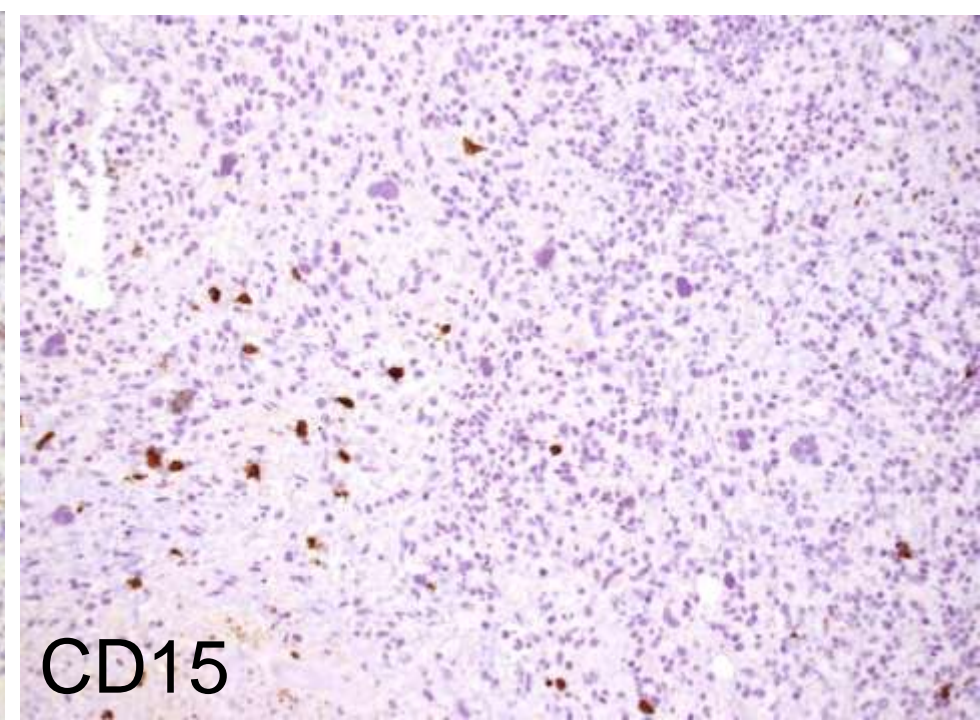
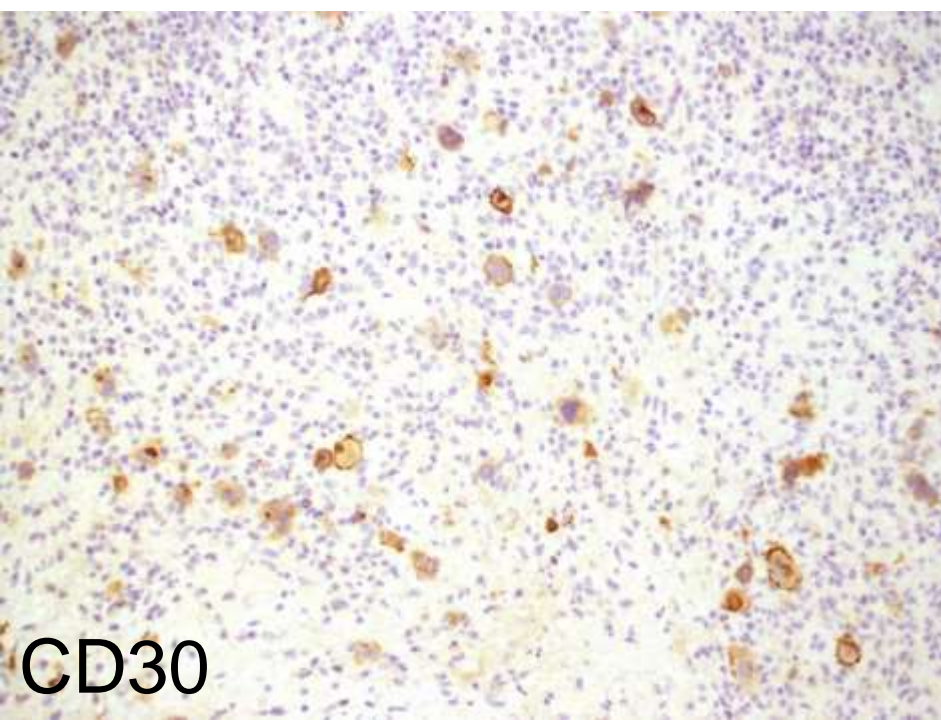
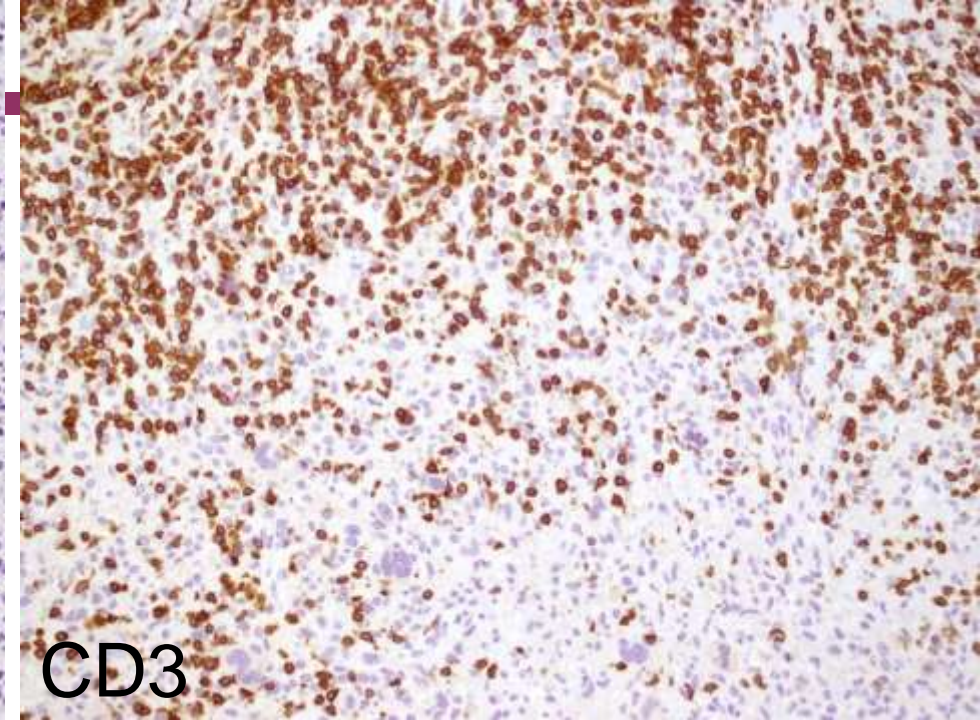
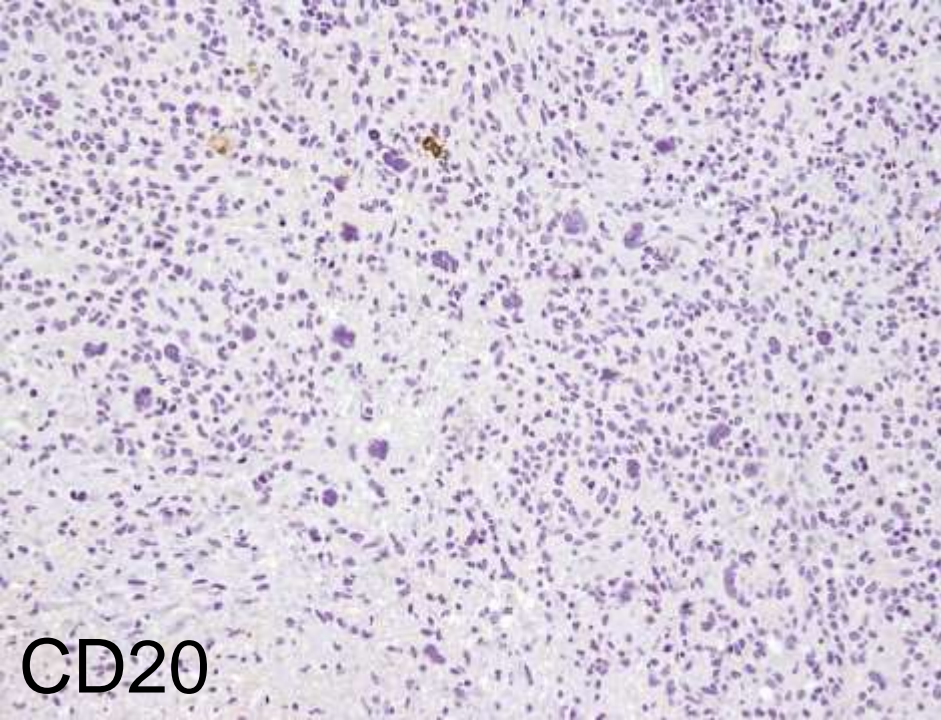
CASE 4

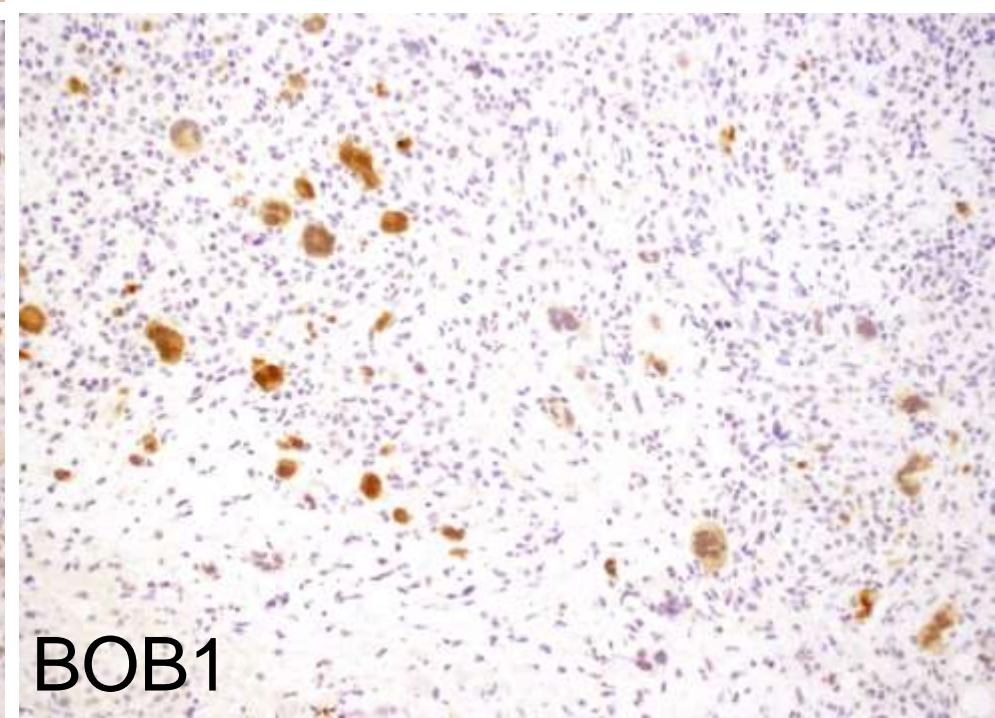
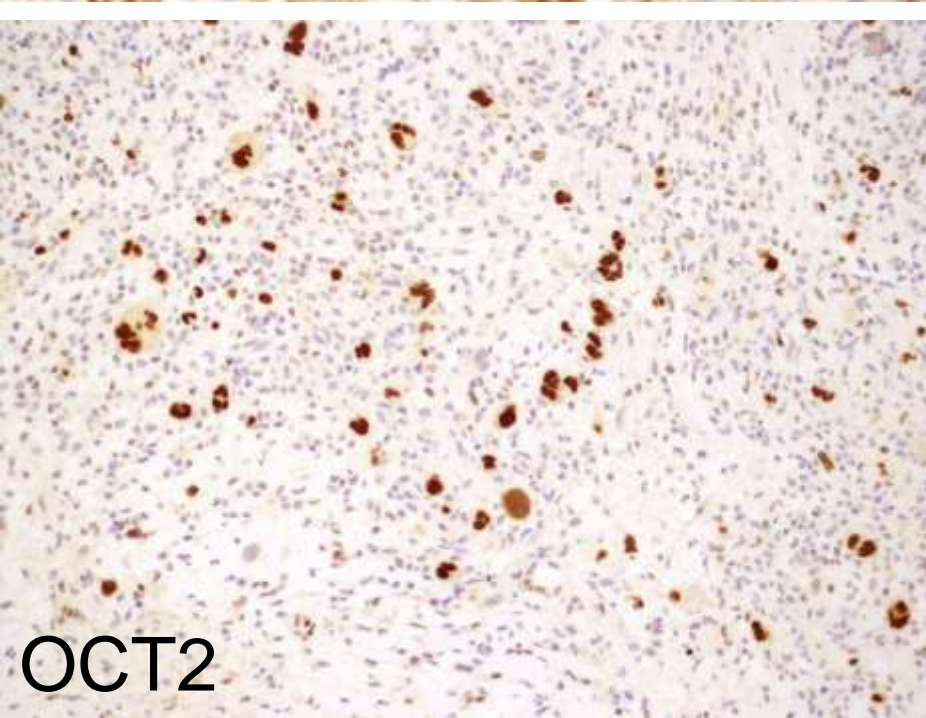
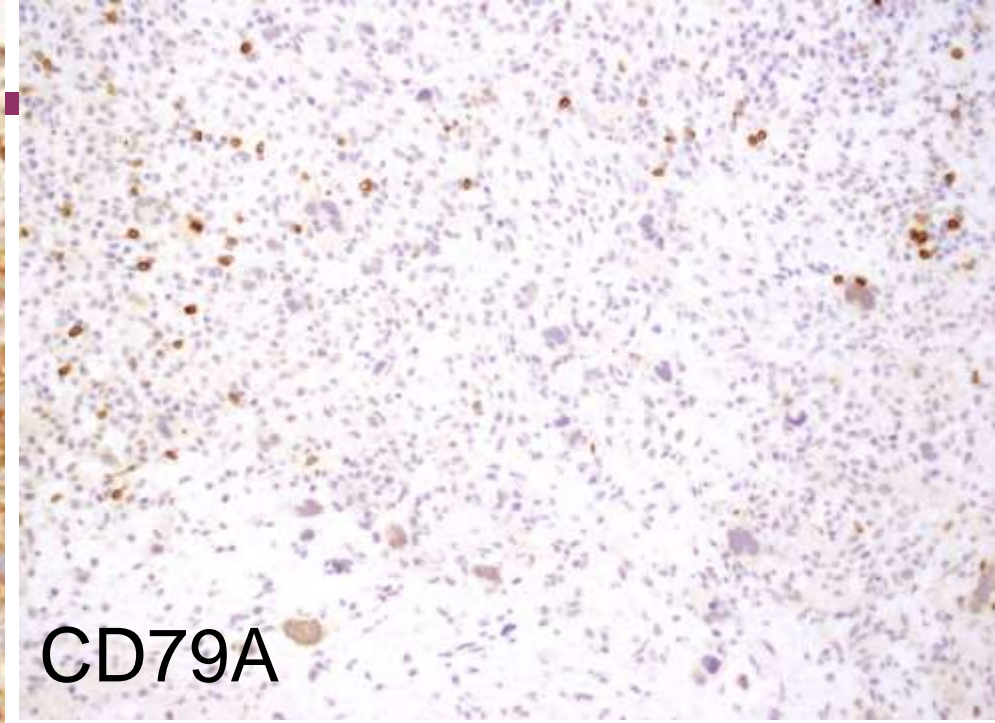
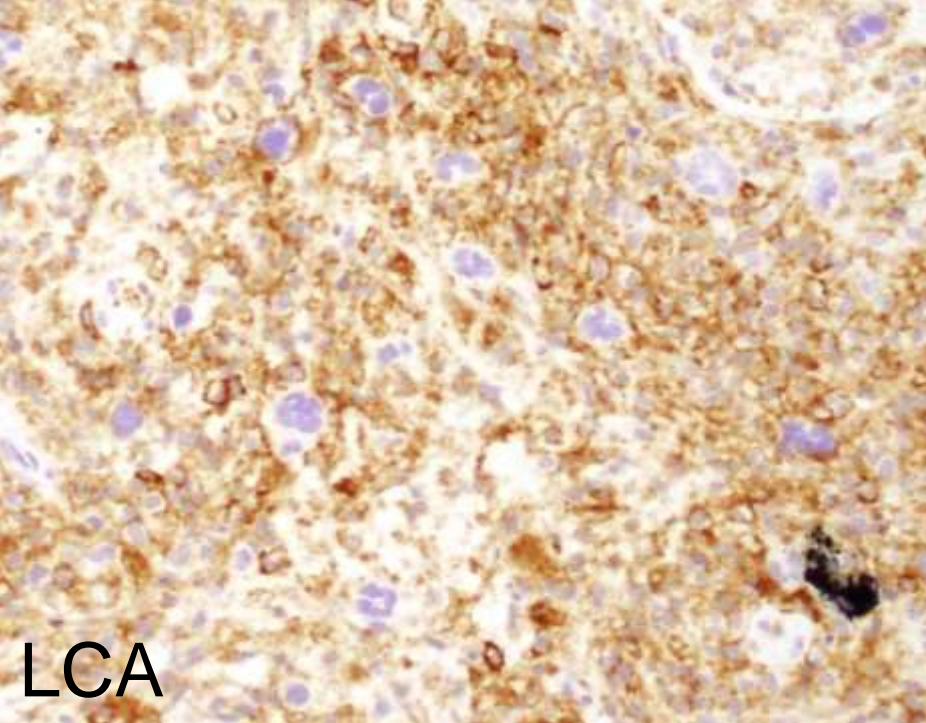
- 78 / Man with parotid mass, skin and scalp lesions
- CT scan showed cervical and axillary lymphadenopathy
- No history of immune deficiency

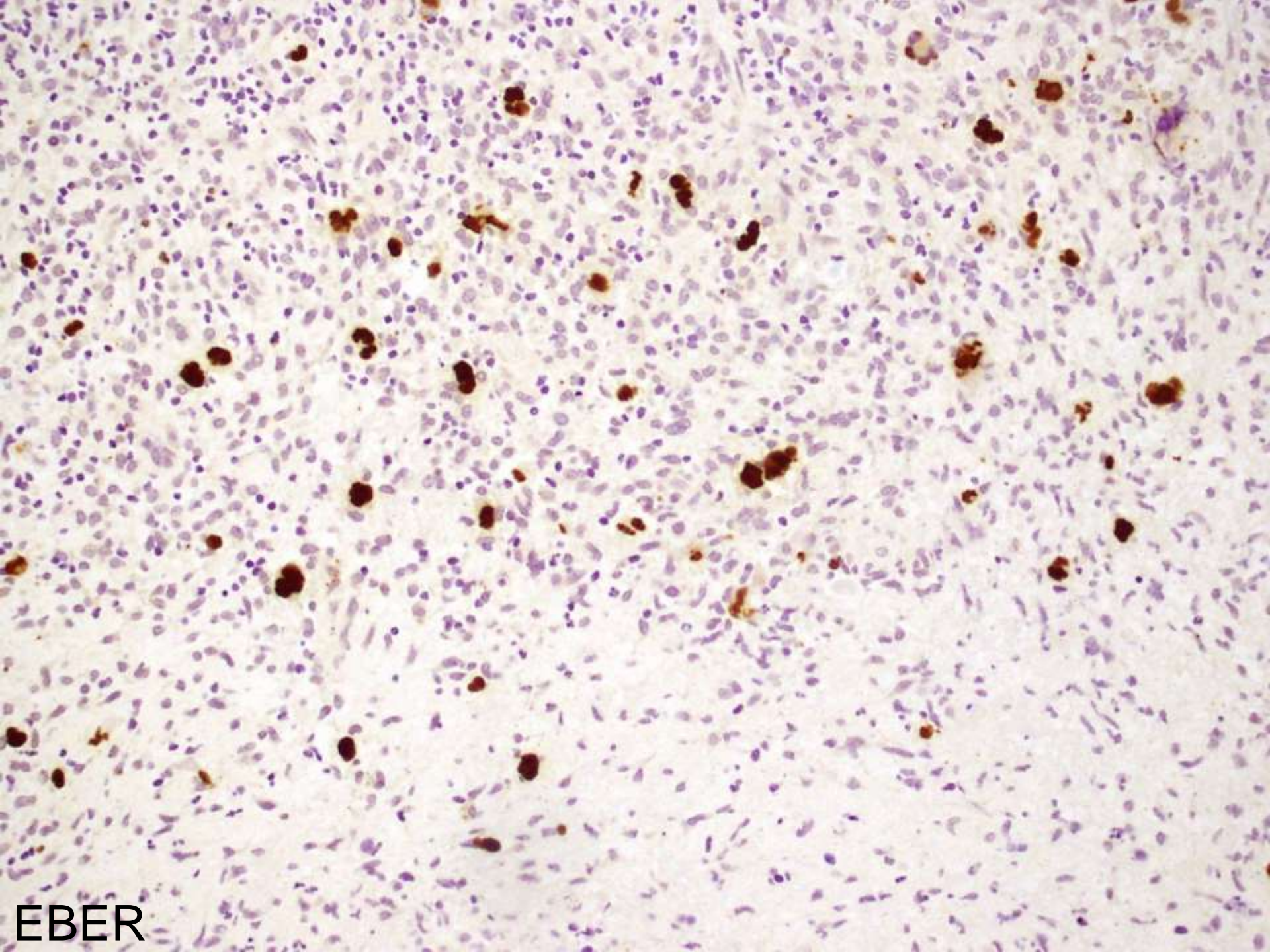












EBER

CASE 4

WHAT'S
YOUR
DIAGNOSIS?

- A. Mucocutaneous Ulcer
- B. EBV+ Diffuse large B cell lymphoma, NOS
- C. Classical Hodgkin Lymphoma
- D. Lymphomatoid granulomatosis

EBV+ MUCOCUTANEOUS ULCER

- MCU occurs in elderly patients with immunosuppression
 - Iatrogenic: azathioprine, cyclosporine, or methotrexate
 - Post-transplantation
 - age-related immunosenescence
- Mean age: >70 yrs
- Clinical:
 - **Localized, solitary, sharply demarcated ulcerative lesions**
 - oropharynx mucosa and skin (lips, arms trunk)
 - large bowel and rectum (less common)
 - Isolated regional LN
 - **No systemic LAD, organomegaly, BM involvement**

EBV+ MUCOCUTANEOUS ULCER

- Pathology
 - shallow, mucosal or cutaneous ulcers, well demarcated
 - Mixed inflammatory infiltrate with rim of reactive T cells at base
 - Large immunoblasts and RS-like cells
 - Positive for B-markers, CD20 +/-, CD30+, CD15+/-, CD45+/-, EBER+
- Clonality: less than 50% monoclonal
- Outcome: Indolent, spontaneous regression (25-45%)
- Differential diagnosis
 - CHL (skin involvement): CHL rarely presents with extranodal disease
 - LYG (skin involvement)
 - EBV+ DLBCL NOS

EBV+ DLBCL NOS

- This term replaces “EBV+ DLBCL of the elderly”, because EBV+ DLBCL can occur in all age groups (no more age cut off of 50 yrs)
- No known or undiagnosed immunodeficiency or prior lymphoma.
- Must exclude other EBV-related LPD (LyG, MCU, IMS, PEL etc)
- In older patients, related to senescence of the immune system.
- More common in Asia (up to 10% of DLBCL)
- 70% extranodal, 30% nodal alone

EBV+ DLBCL NOS*

■ Histology

- varies from polymorphous (similar to PTLD) to monomorphous
- Geographical necrosis and RS-like cells common

■ IHC

- Most cases CD20+, CD79a+, MUM1+, CD10-, BCL6-
- RS-like cells EBV+, CD20+, CD30+ (75%), CD15-

■ Clonal IgH PCR

- Distinguish from infectious mononucleosis of the elderly

DIFFERENTIAL DIAGNOSIS

| | MCU | CHL |
|-----------|--|--|
| Skin | Skin and oropharyngeal mucosa, colon, rectum | Never presents primarily in skin, skin involvement in rare cases due to direct extension |
| EBV | + | +/- |
| LCA | + | - |
| B-markers | + | - (except PAX5 and CD20 variable) |

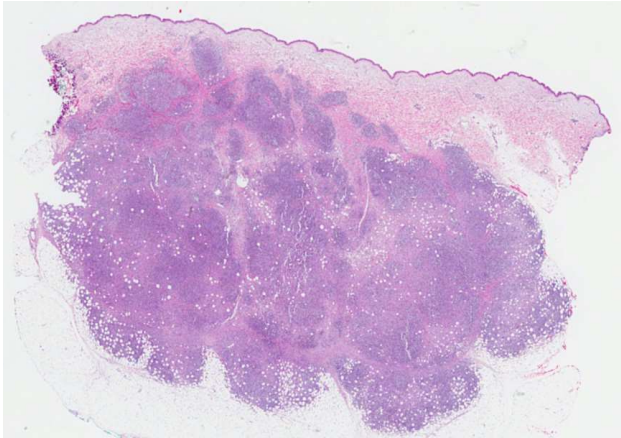
| | MCU | EBV+ DLBCL |
|--------------|----------------------------------|--------------------------------------|
| Presentation | Localised to mucocutaneous sites | Systemic. Isolated skin disease rare |
| Outcome | Self limiting | Aggressive clinical course |

DIFFERENTIAL DIAGNOSIS

| | MCU | LYG |
|------------------------------|---|--|
| Presentation | <ul style="list-style-type: none">• Localised to mucocutaneous sites• Shallow ulcer, well circumscribed | <ul style="list-style-type: none">• Lung (>90%) +/- skin, CNS, liver, kidney.• Mucosal site uncommon. |
| Necrosis and angiocentricity | Can be present | present |
| Outcome | Self limiting | Variable, depends on grade |

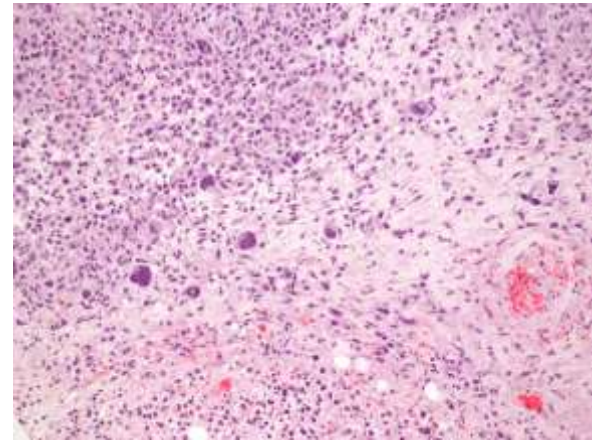
WHAT IS THE DIAGNOSIS ?

Case 3



- 70/F, multiple skin lesions, well demarcated
- EBV+ LBCL

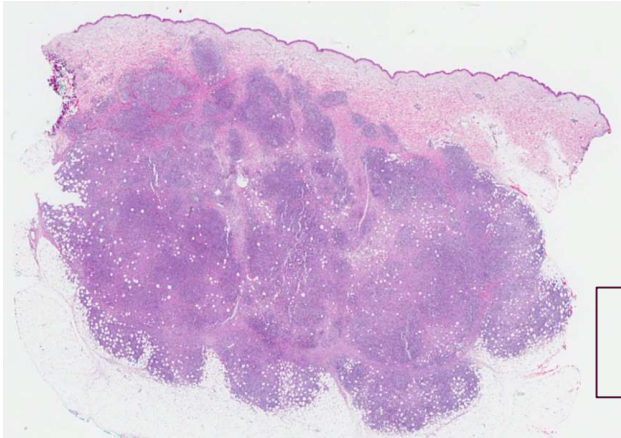
Case 4



- 78/M, parotid and skin lesions, cervical and axillary LAD
- EBV+ LBC proliferation with necrosis and RS-like cells

WHAT IS THE DIAGNOSIS ?

Case 3

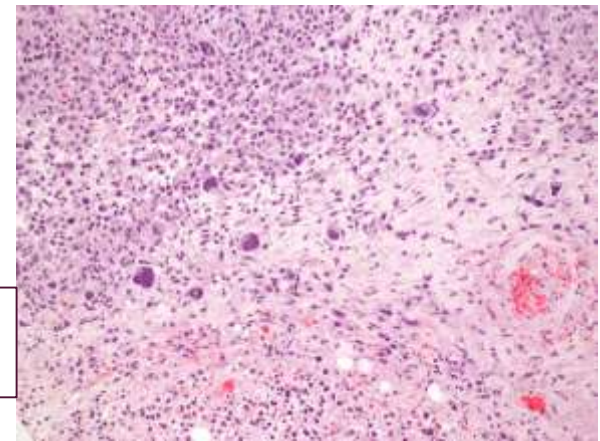


MCU

DLBCL EBV+

- 70/F, multiple skin lesions, well demarcated
- EBV+ LBCL

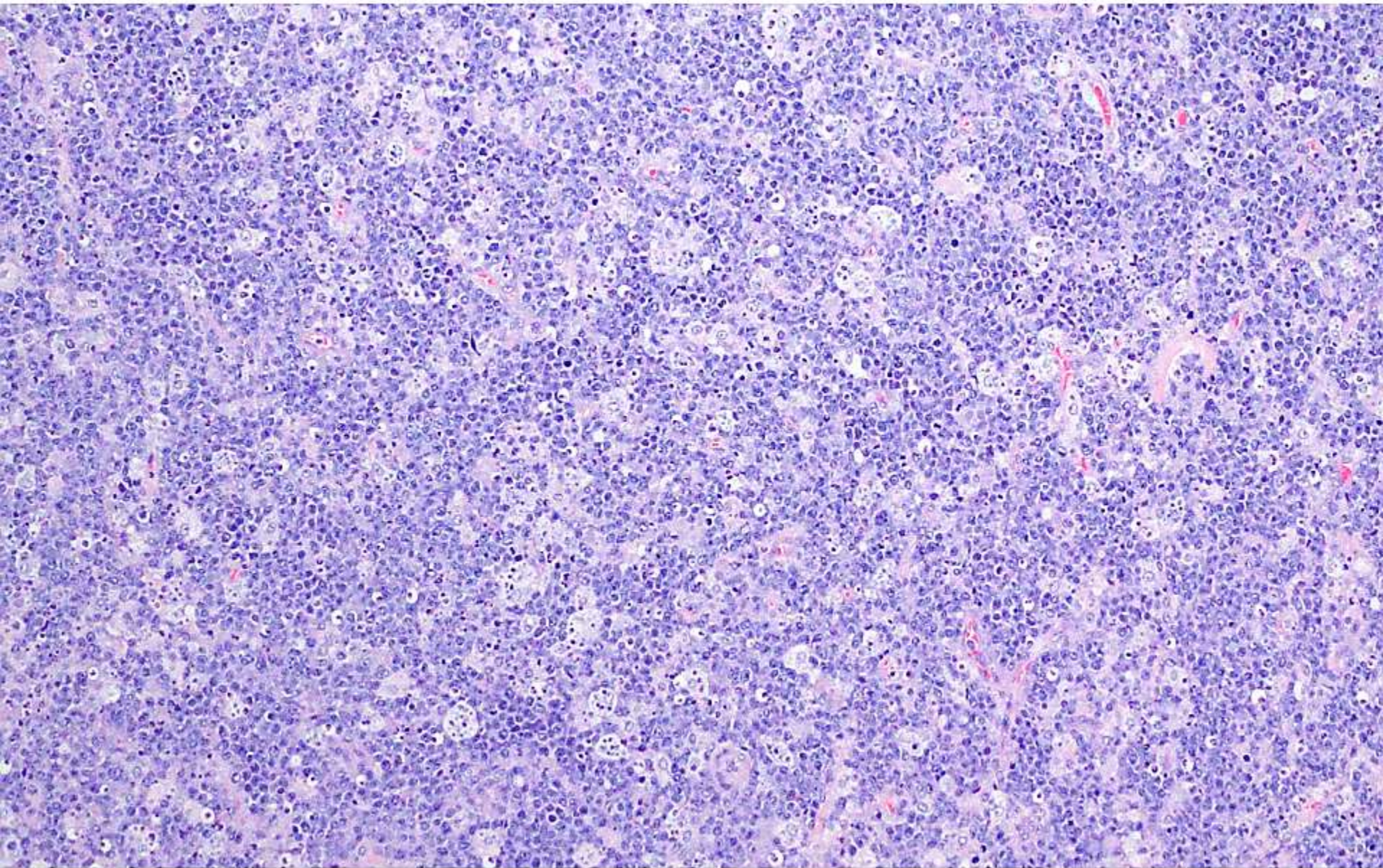
Case 5



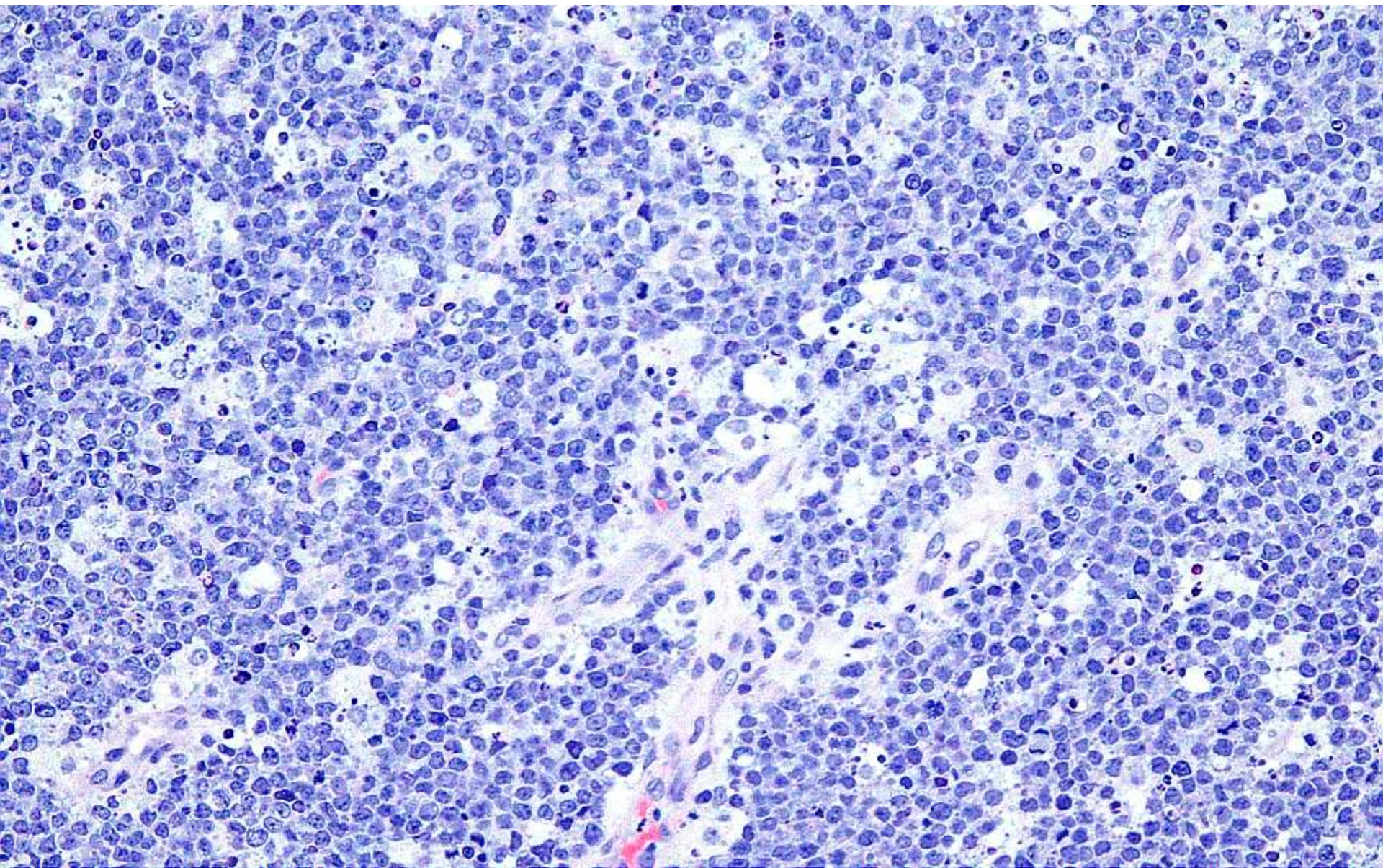
- 78/M, parotid and skin lesions, cervical and axillary LAD
- EBV+ LBC proliferation with necrosis and RS-like cells

CASE 5 - HISTORY

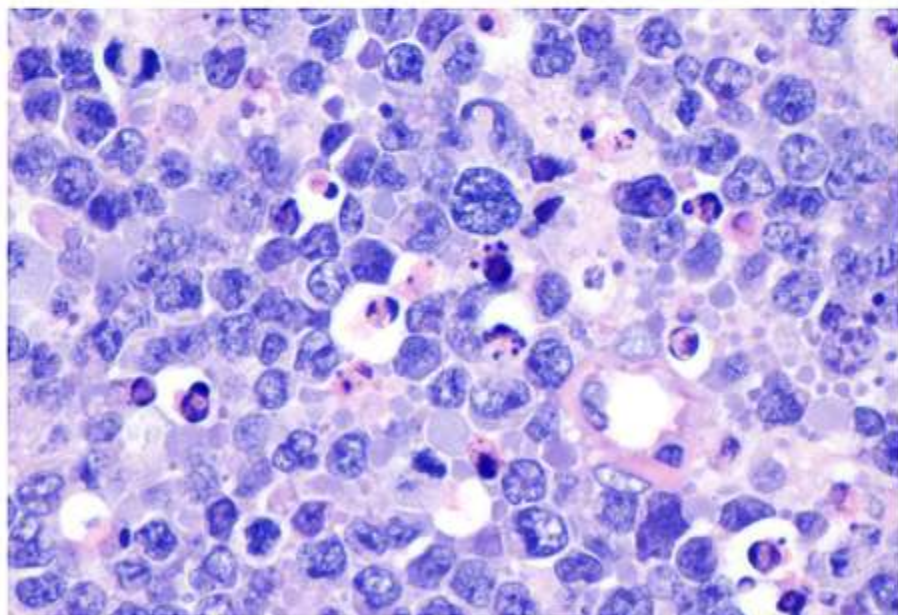
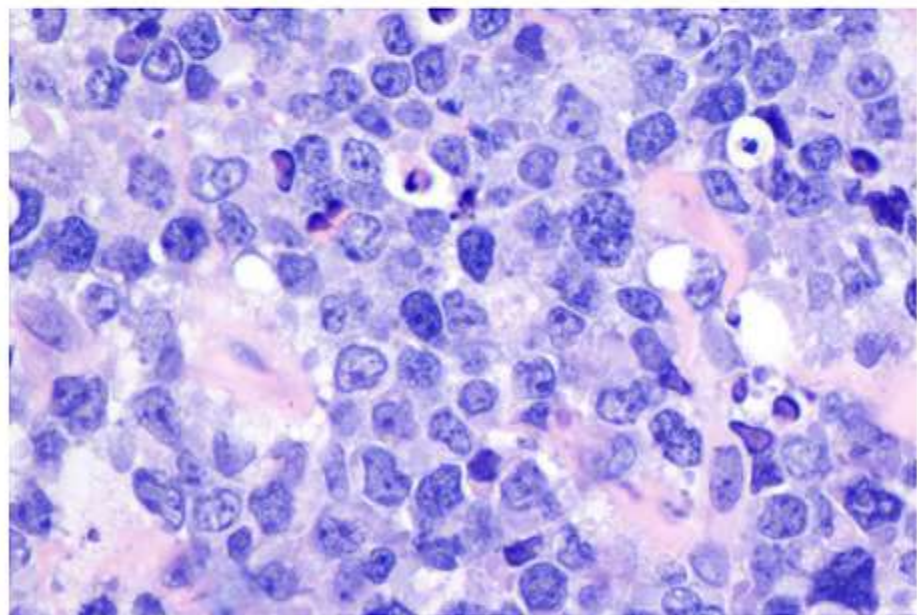
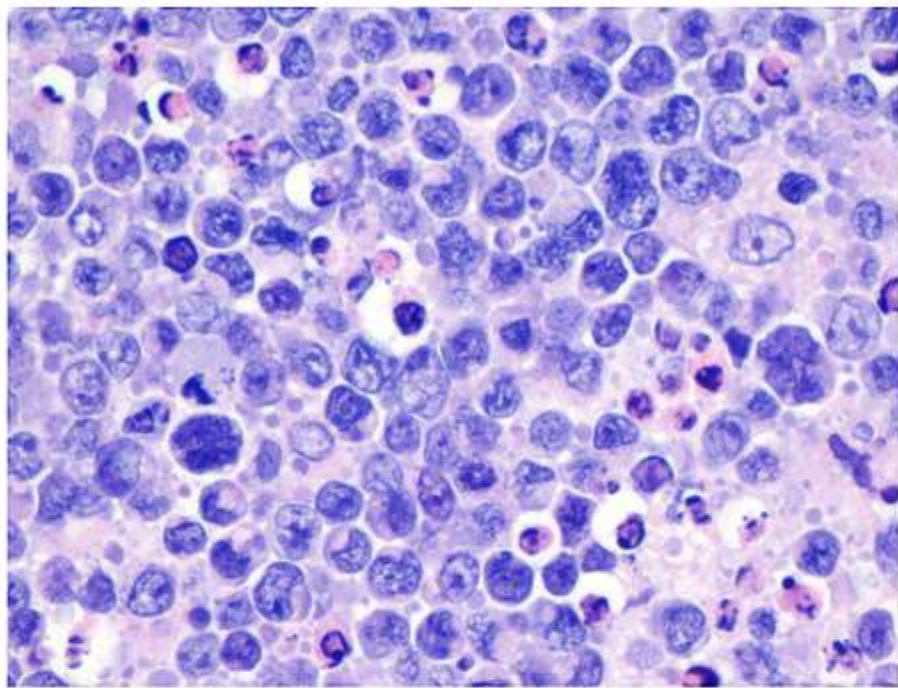
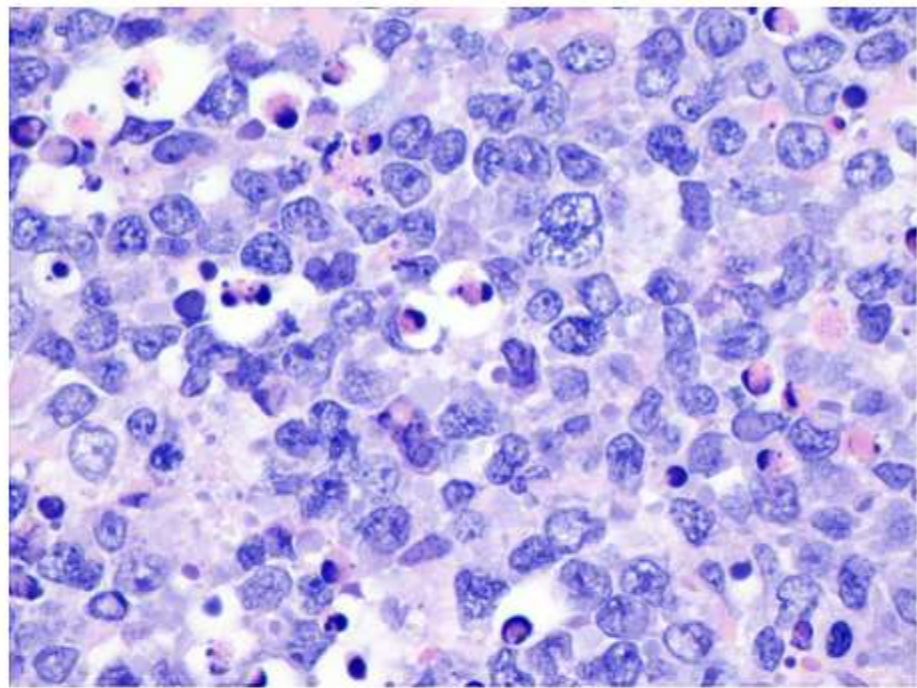
- 17 year old male foreigner
- Presents with rapidly enlarging left neck mass



Diffuse, monotonous lymphoid proliferation

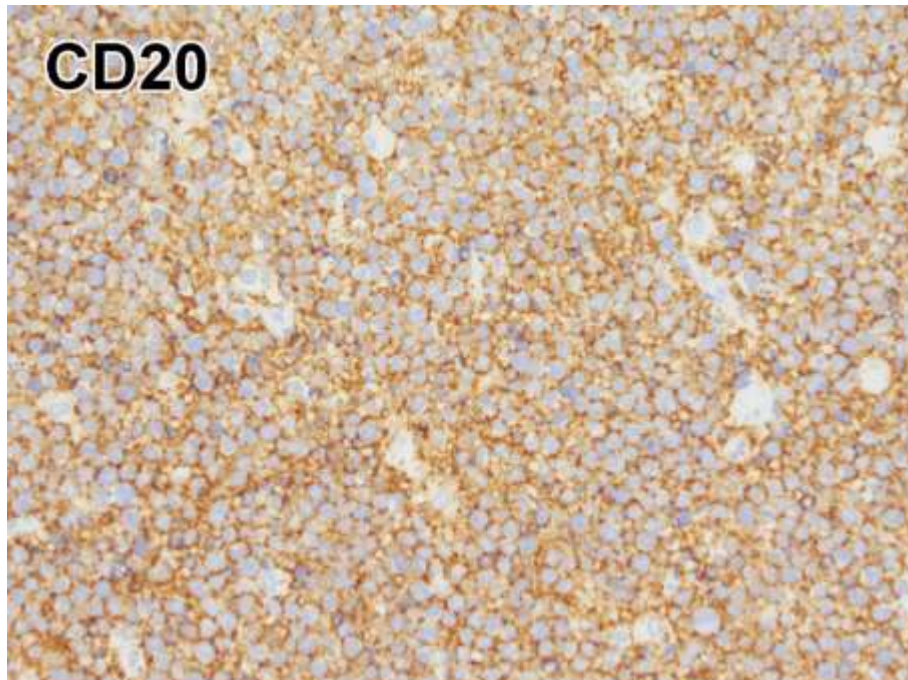


Diffuse, monotonous lymphoid proliferation with starry sky appearance

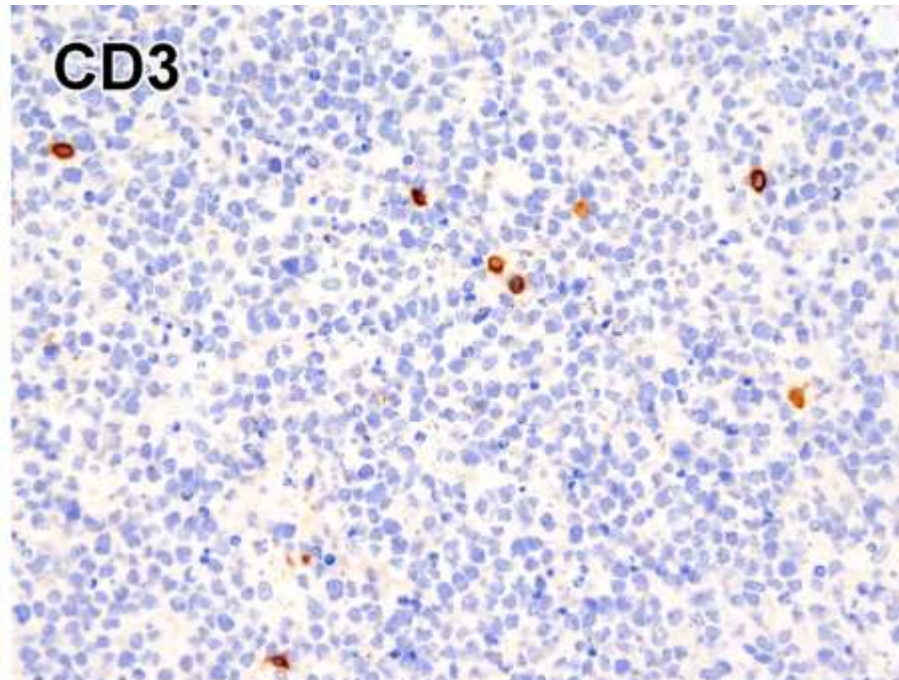


More cytologic pleomorphism than classic BL

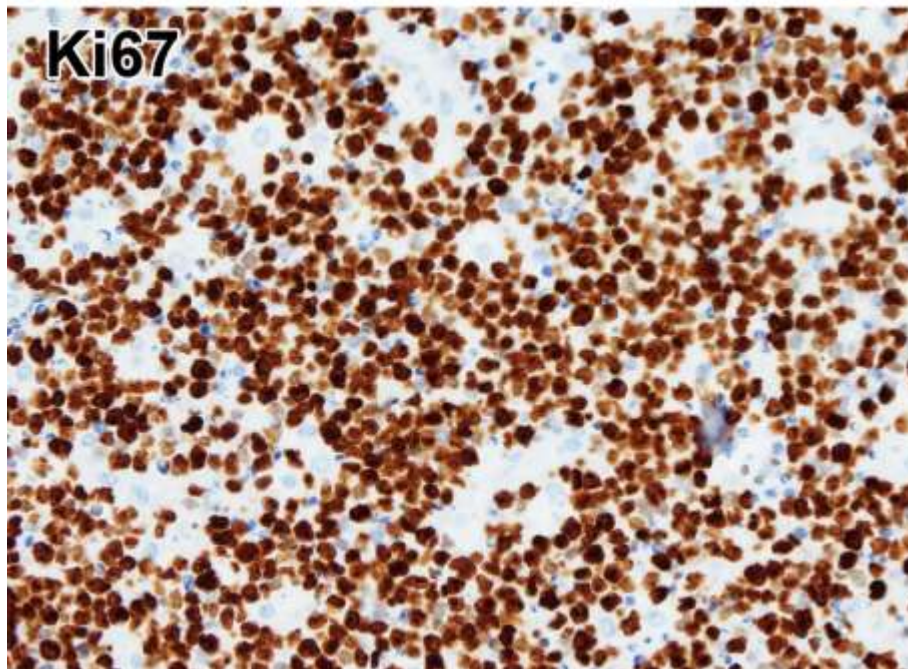
CD20



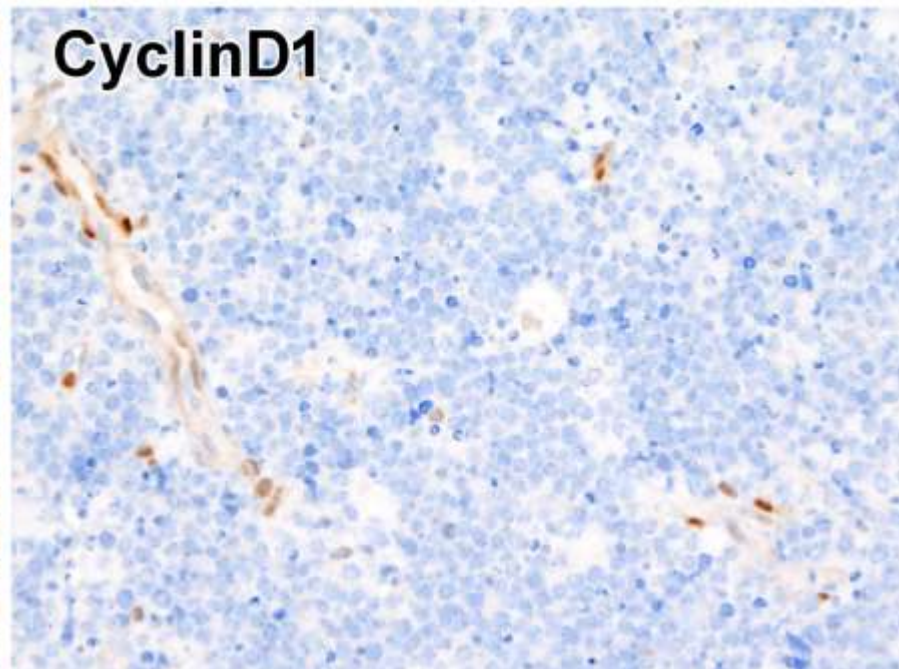
CD3

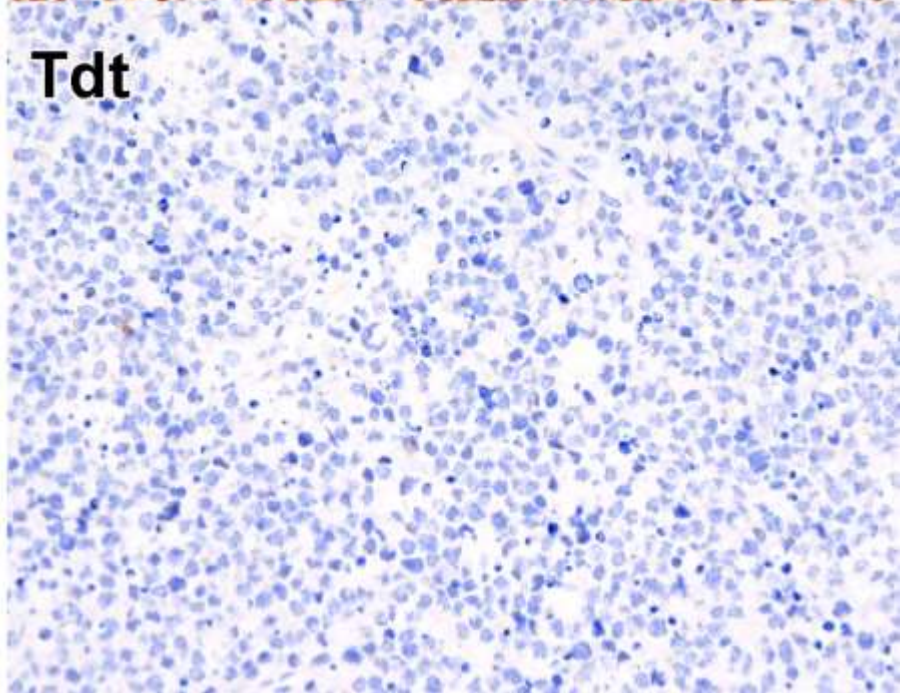
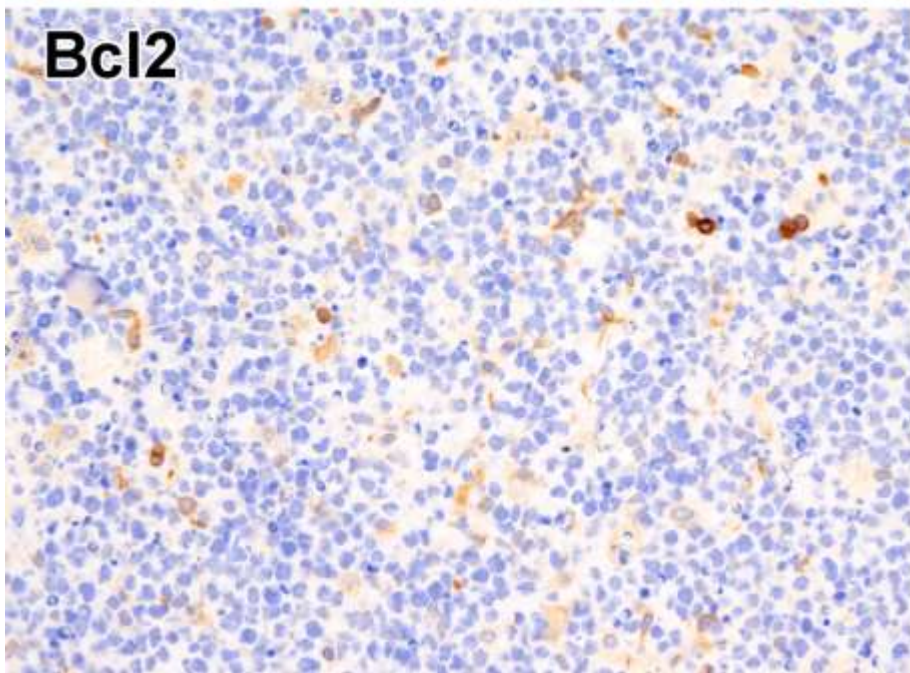
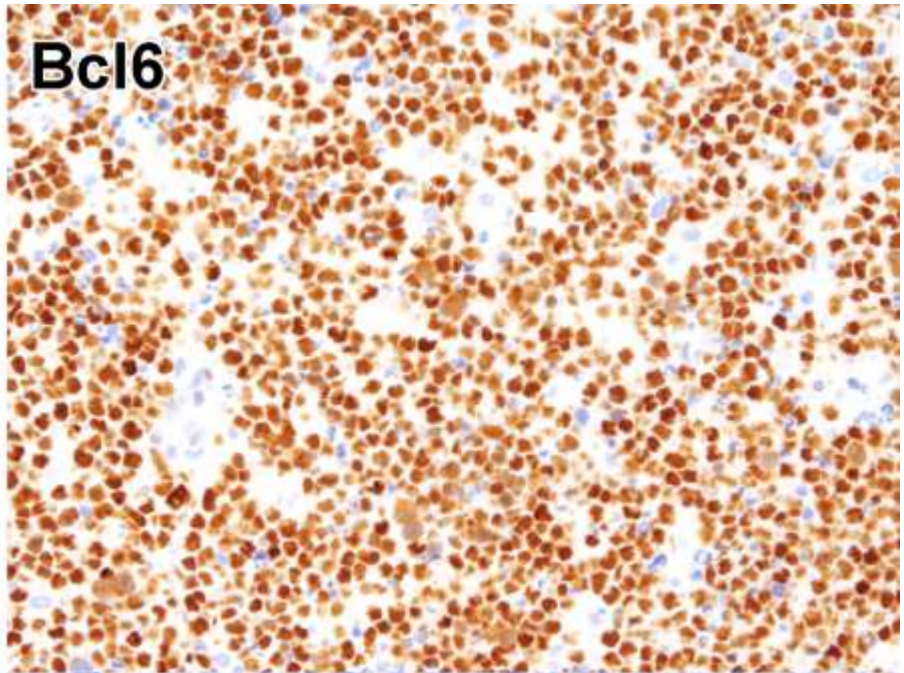
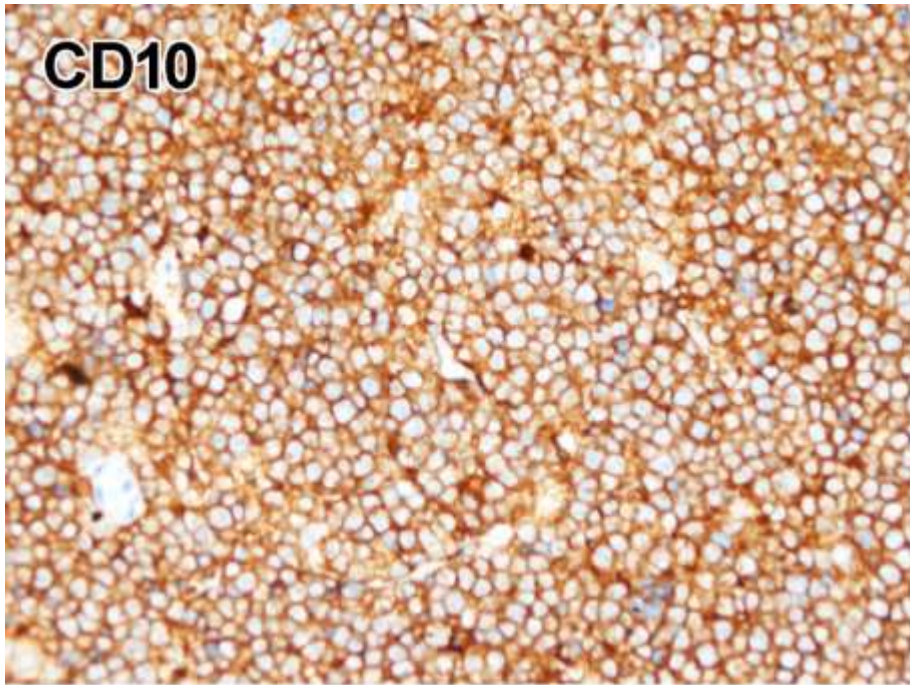


Ki67

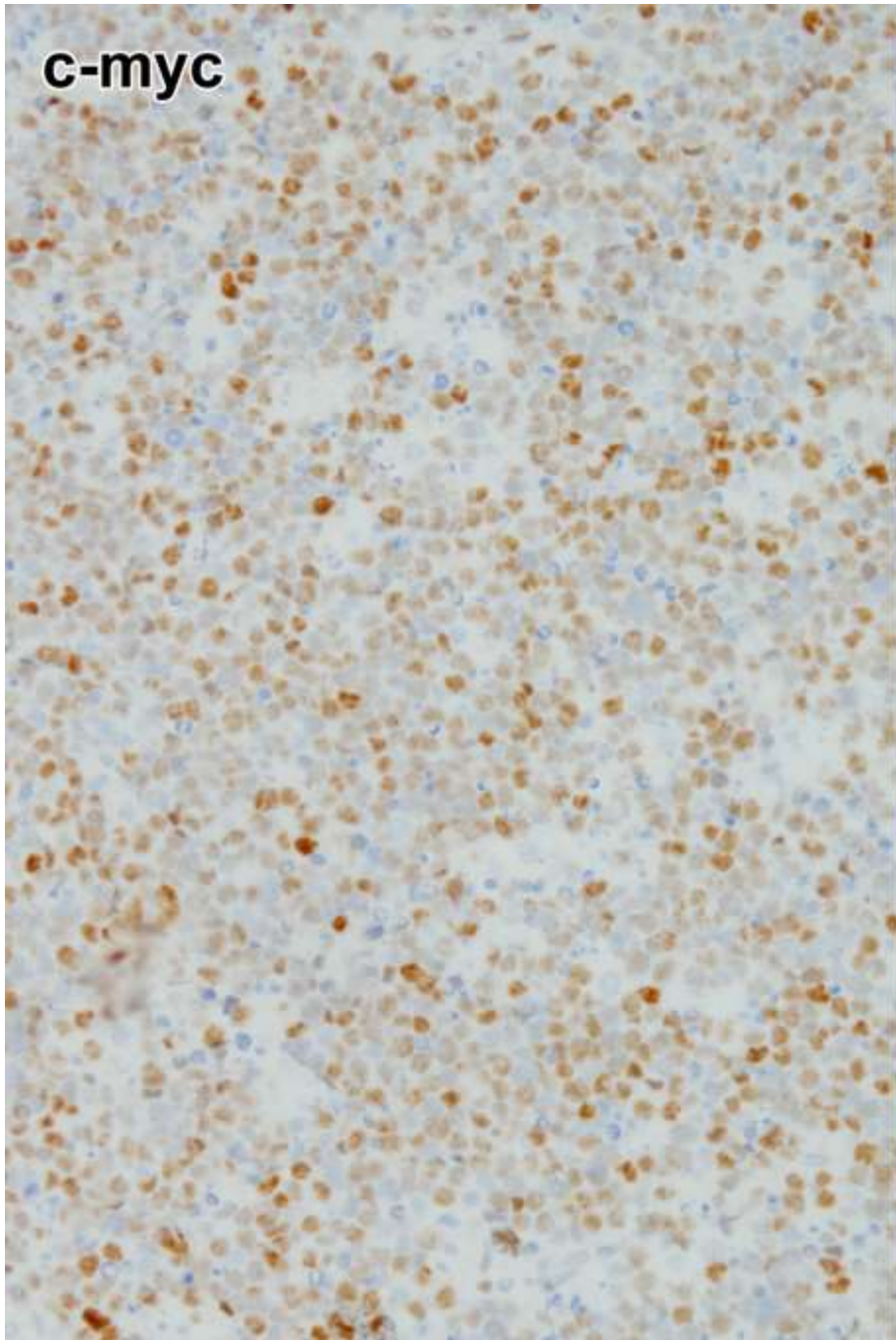


CyclinD1

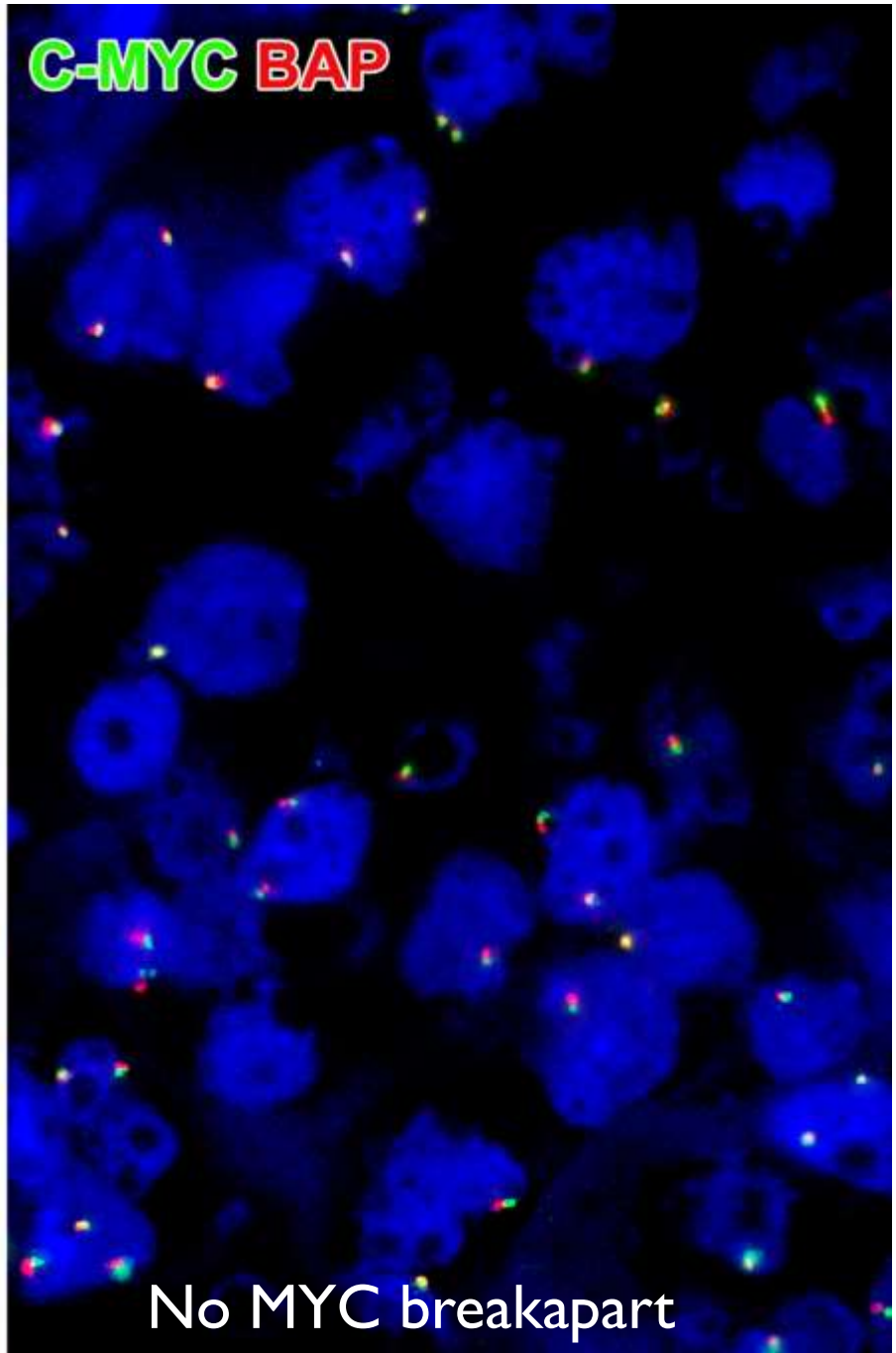




c-myc



C-MYC BAP

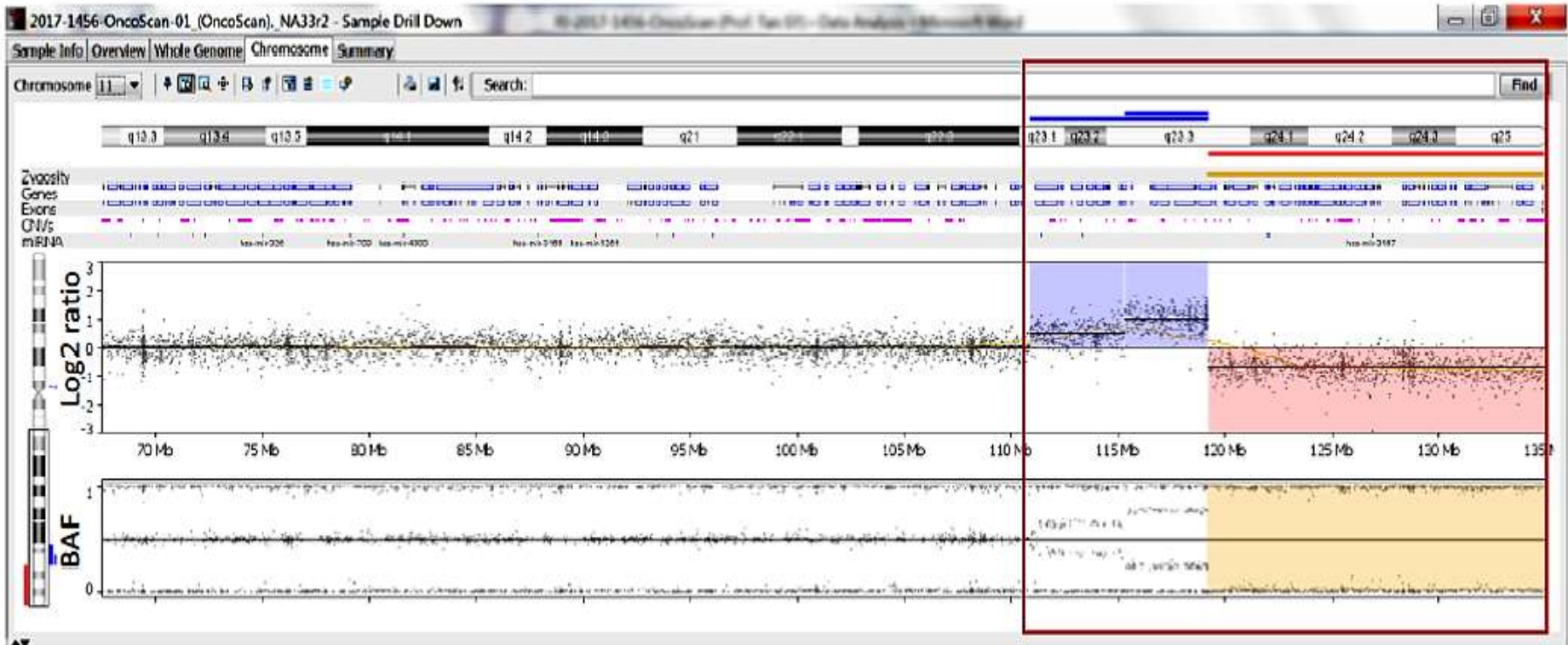


No MYC breakapart

CASE 5

WHAT'S YOUR DIAGNOSIS?

- A. DLBCL
- B. Burkitt lymphoma with no MYC translocation
- C. Burkitt like lymphoma with 11q abnormalities
- D. High grade B cell lymphoma



Copy number variation analysis shows gains of 11q23.1-11q23.3 (CN=3) and 11q23.3 (CN=4) and copy number loss (CN=1) at 11q23.3-11q25

Diagnosis: Burkitt-like lymphoma with 11q aberrations

Burkitt-like Lymphoma With 11q Aberrations

- Subset of lymphomas that resemble BL by morphology and phenotype BUT
 - lack MYC rearrangements
 - 11q alterations (gains and losses)
- Experience is limited but clinical course seems to be similar to BL

HIGH GRADE B CELL LYMPHOMA

- Previous category “BCL, unclassifiable, with features intermediate between DLBCL and BL” can be reclassified into

HG-BCL with MYC/BCL2/BCL6 rearrangements

- All double hit lymphomas irrespective of morphology (DLBCL or BL-like) should be in this category
- Except
 - FL with acquired MYC-T
 - B-LBLL with MYC/BCL2-T

HG-BCL NOS

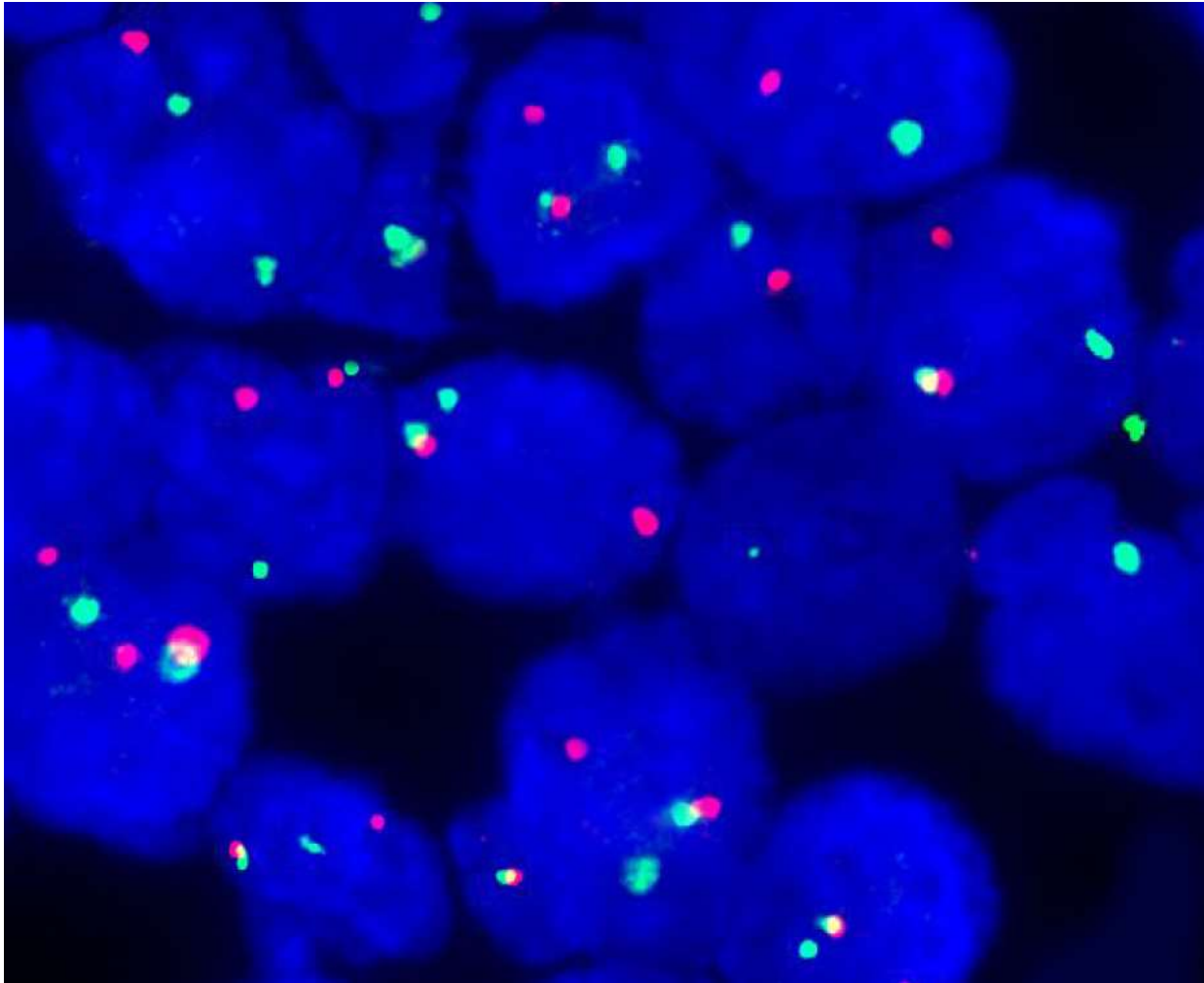
- All other cases with morphology intermediate between DLBCL and BL
- no MYC rearrangement

HGBCL WITH DOUBLE HIT

- Complex karyotype
- Morphology variable: DLBCL, BL, DLBCL/BL, blastoid
- Ki67 proliferation variable
 - Low proliferation does not exclude DHL
- MYC expression variable
 - MYC staining does not correlate with MYC rearrangement
- Majority stage 4, high IPI
- RCHOP ineffective
- Median survival 4.5-18.5 months

MYC PROTEIN EXPRESSION (IHC) IN DLBCL

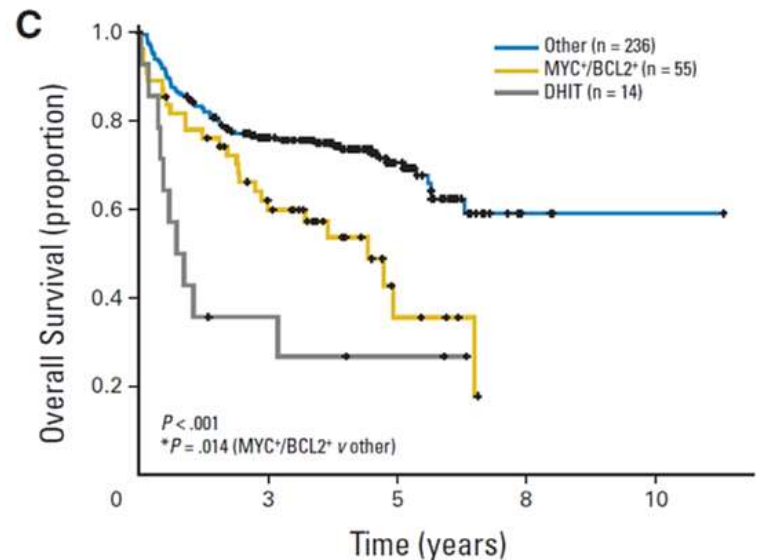
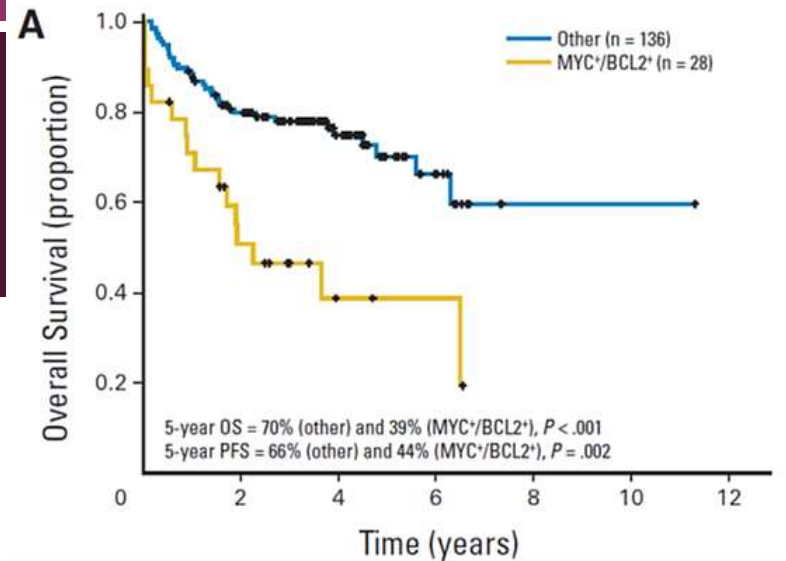
- MYC frequently positive in lymphomas with *MYC* rearrangement (BL and subset of DLBCL)
- 30% of DLBCL show positive MYC expression (40% cut off) but MYC is rearranged in only 5-15% of DLBCL NOS
- DLBCL with MYC expression often lack MYC translocation
- MYC IHC cannot be used as a screening tool to rule out *MYC* translocation in high grade B-cell lymphomas
- Currently, the most reliable way to demonstrate MYC translocation is FISH analysis
 - Should we do FISH for all DLBCL? No consensus
 - Some suggest FISH for MYC if MYC IHC > 40%

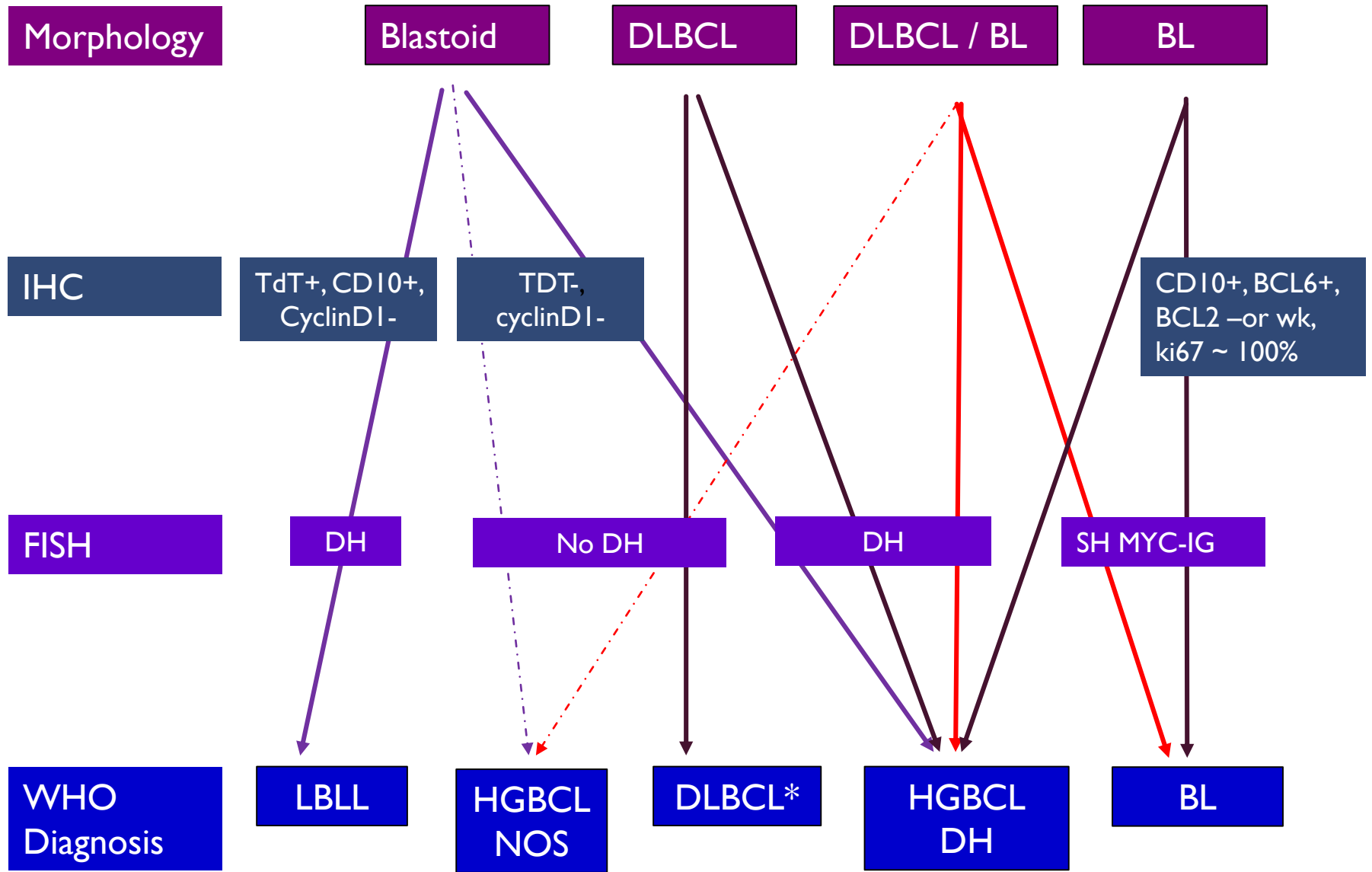


MYC breakapart FISH

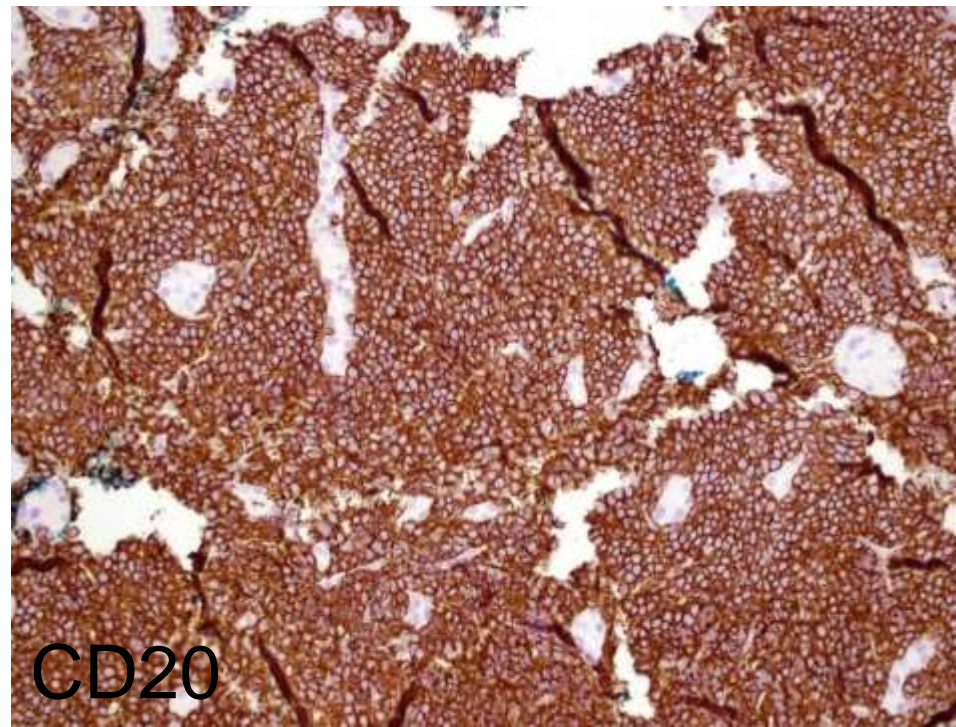
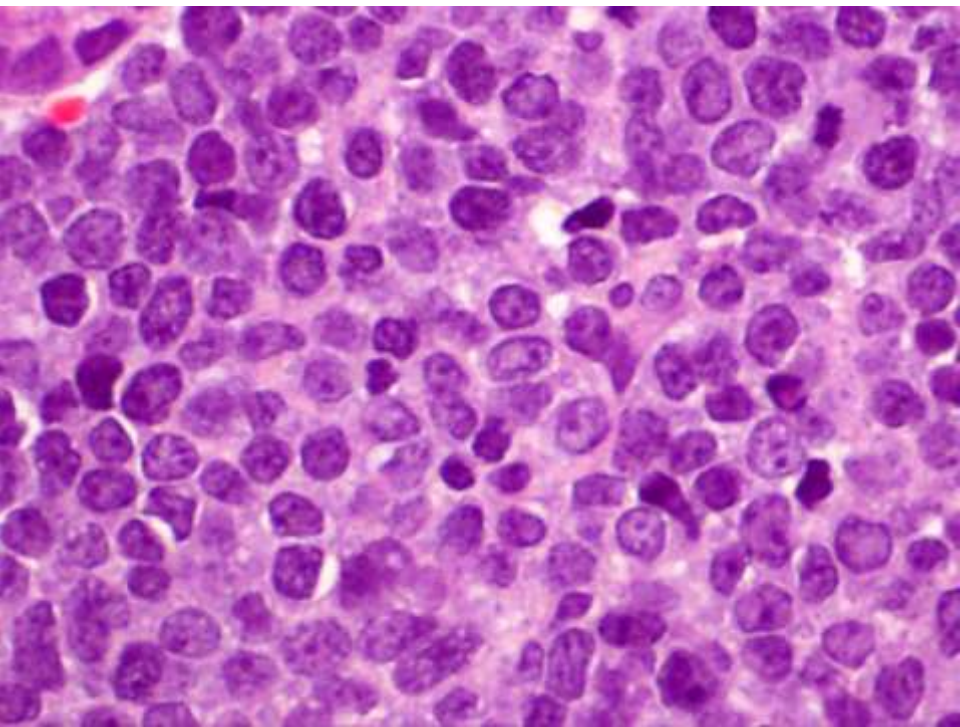
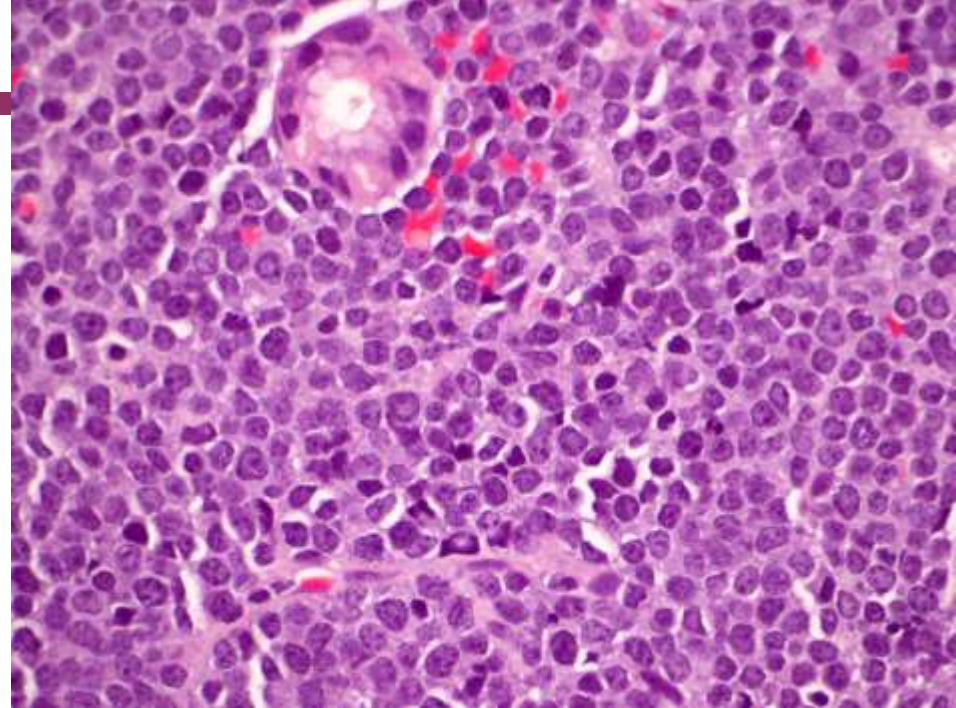
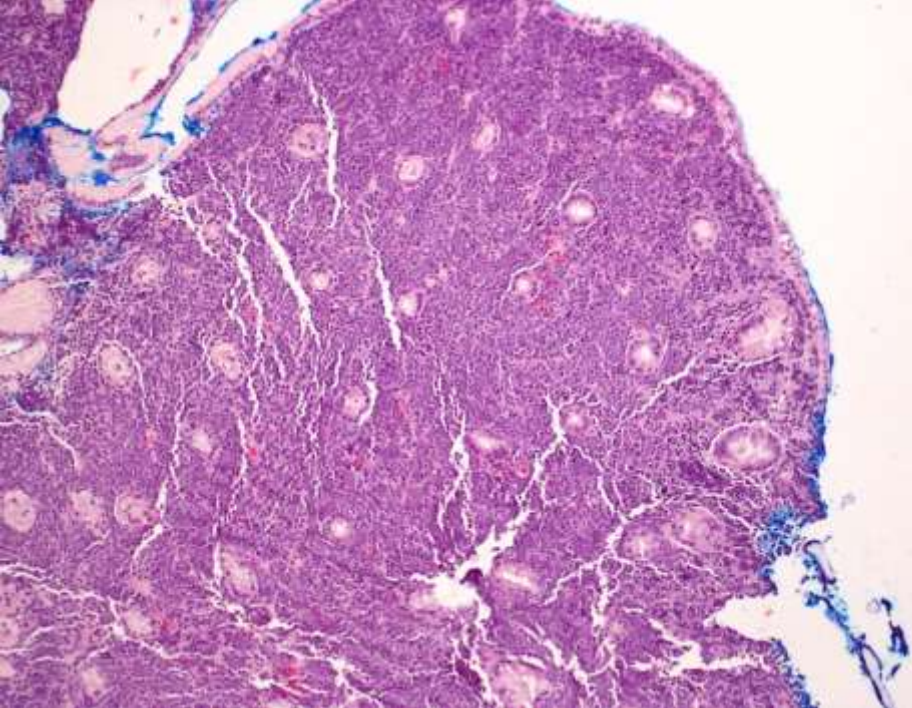
MYC IHC IN DLBCL

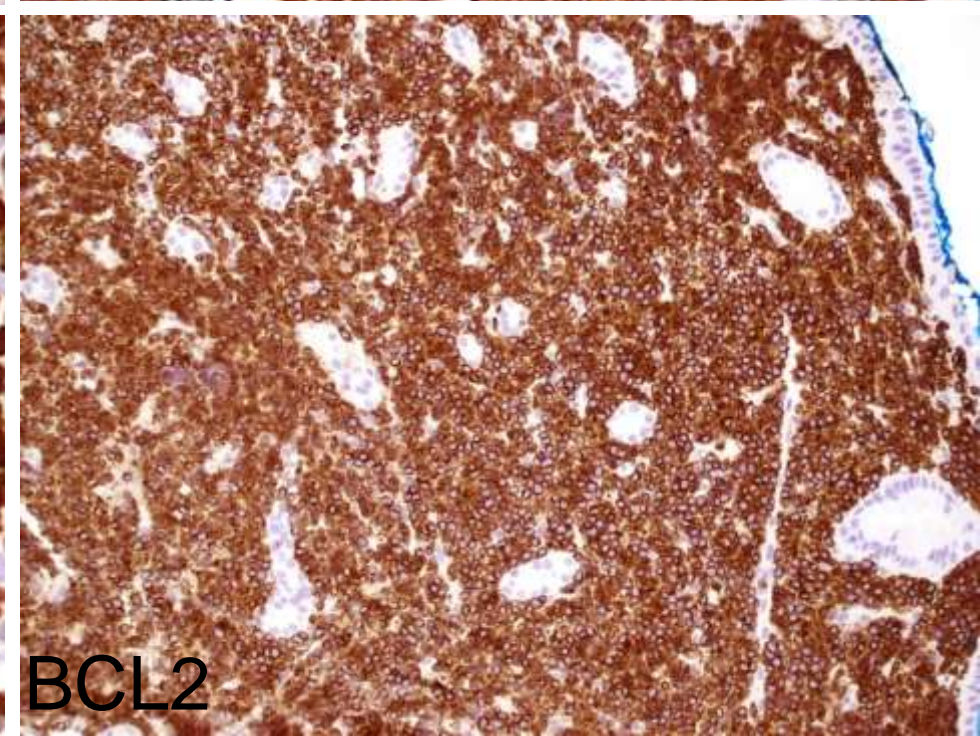
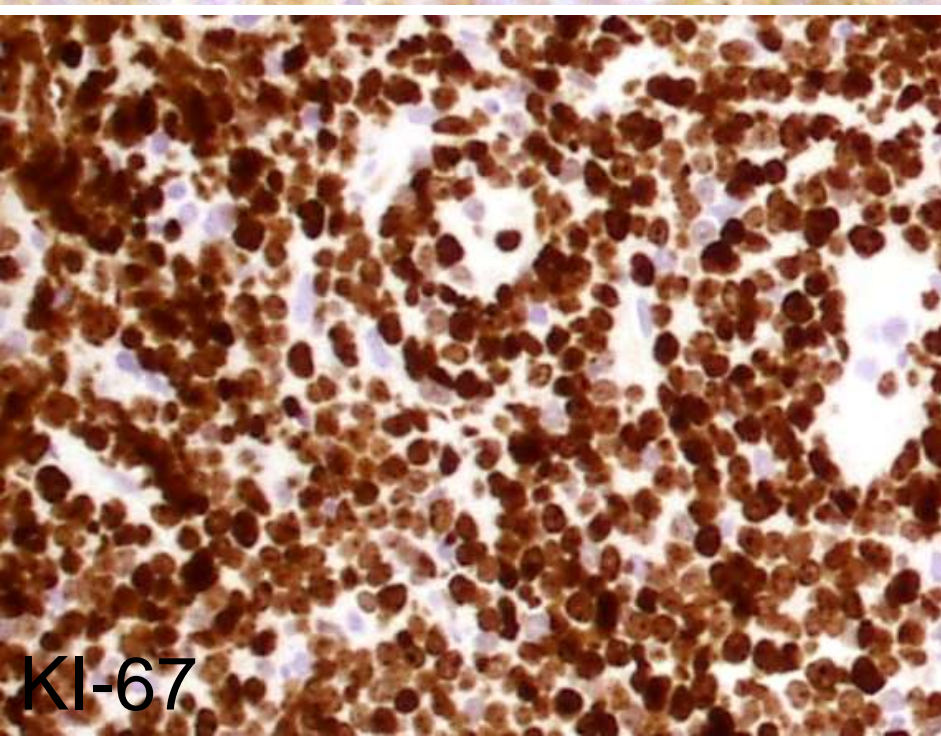
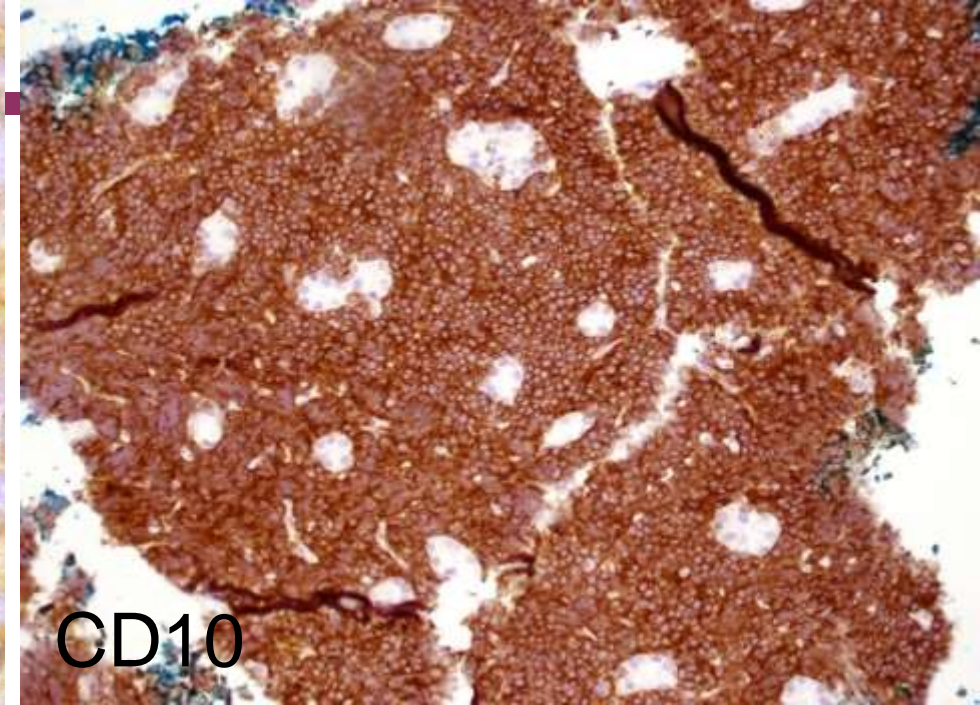
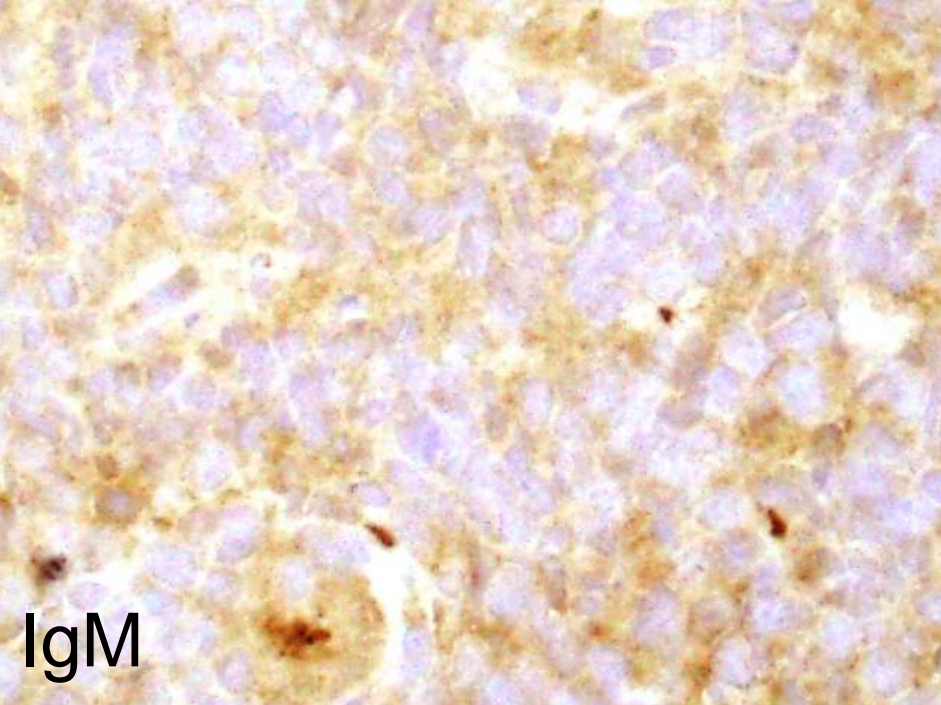
- Double expressors (MYC/BCL2) behave poorly
- Double-hit behaves worse than double-expressors among DLBCLs



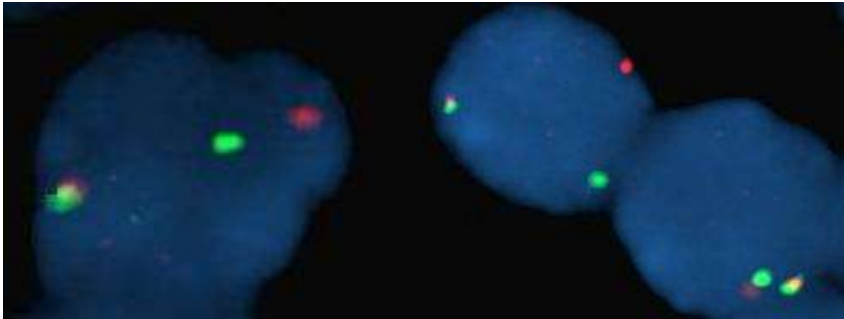


*Includes single MYC-translocation, LBLL;lymphoblastic lymphoma

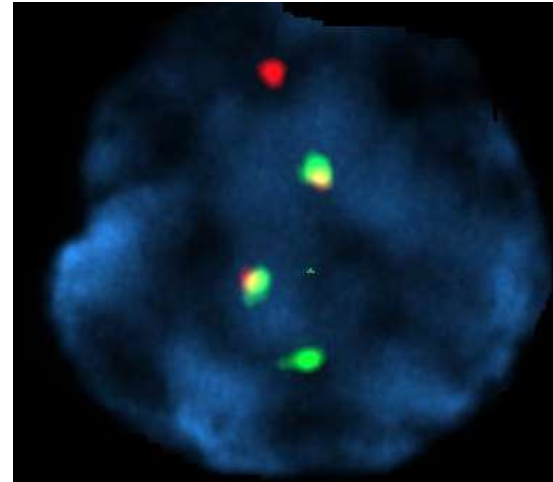




FISH for MYC, breakapart probe



FISH for bcl2/IgH, fusion probe



2008:

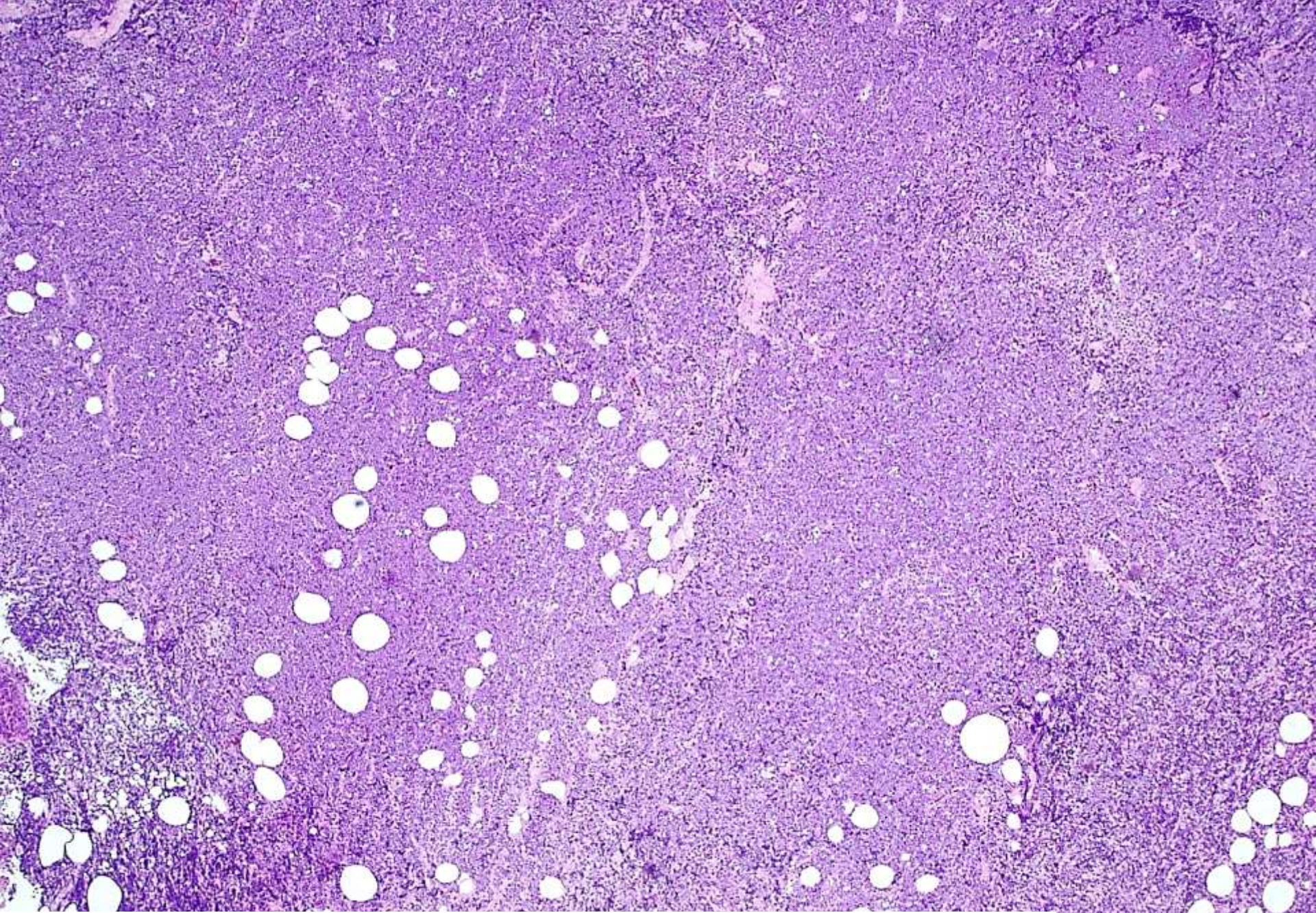
- B-cell lymphoma, unclassifiable, with features intermediate between diffuse large B cell lymphoma and Burkitt Lymphoma

2017:

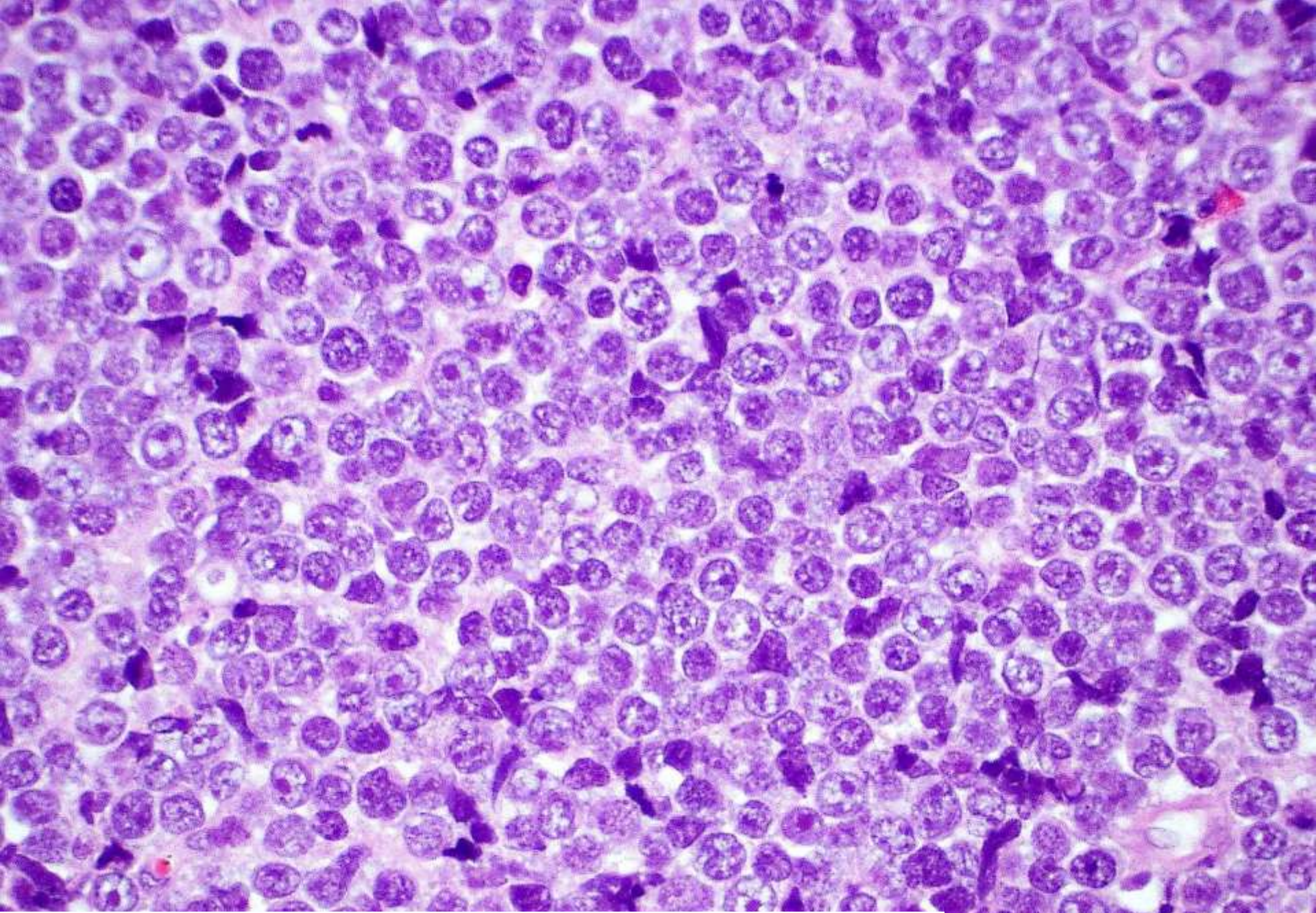
- HG-BCL with MYC/BCL2 rearrangements
('Double Hit' Lymphoma)

CASE 6 HISTORY

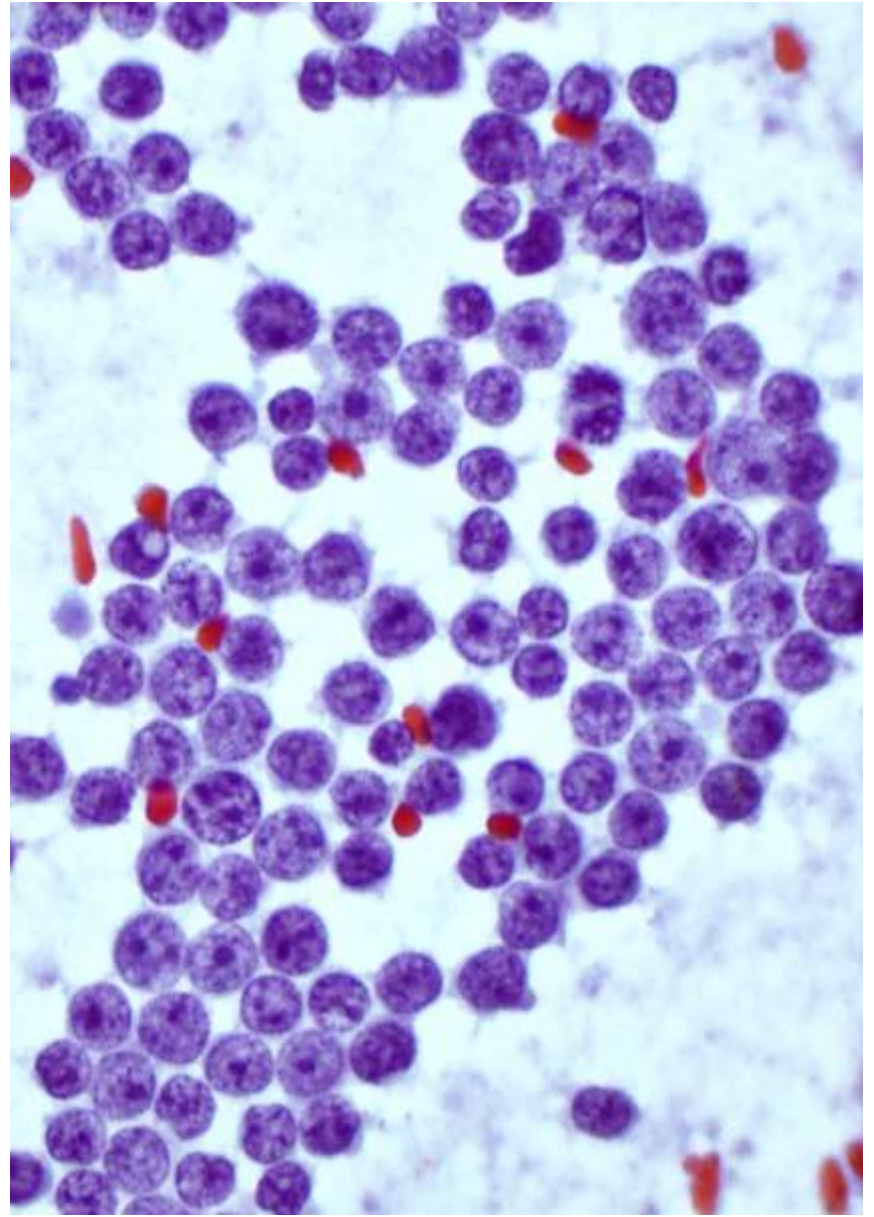
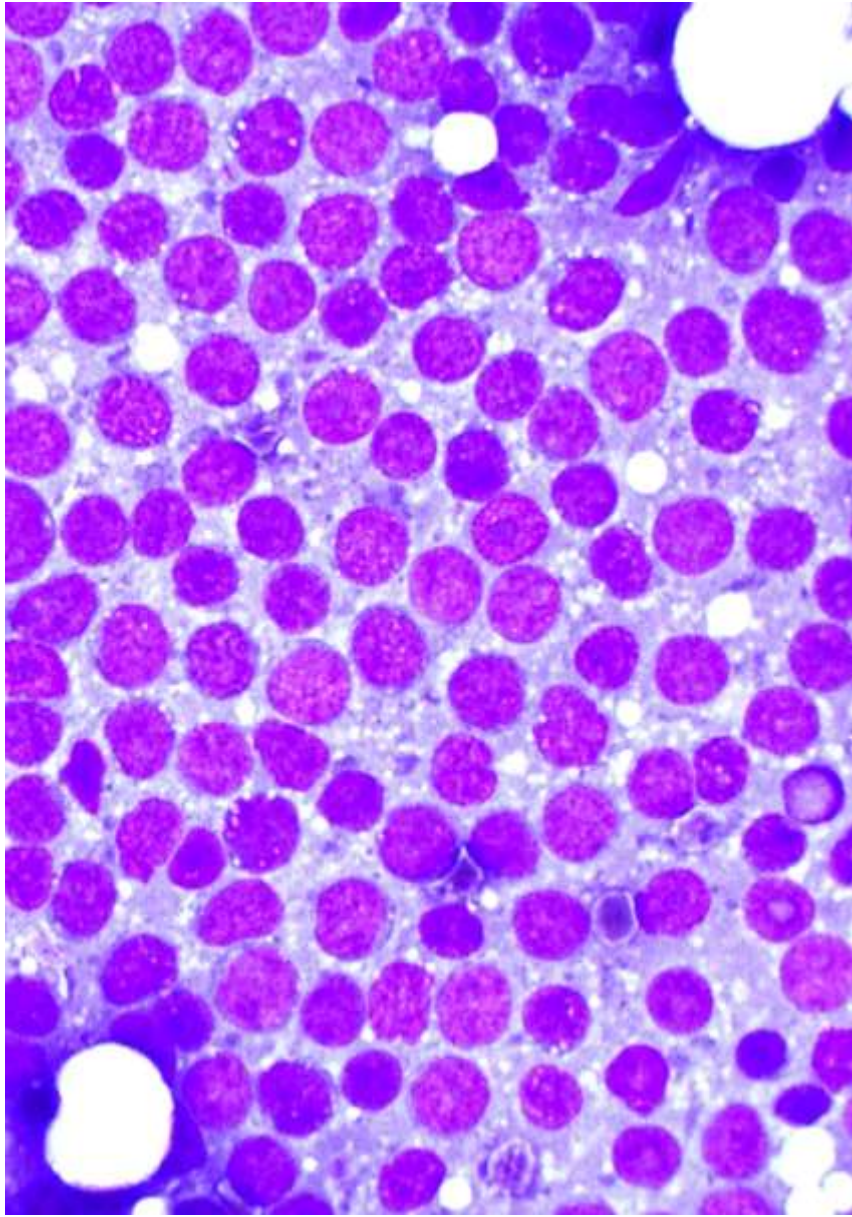
- 63yr / Indonesian / Male
- painless swelling in right inguinal region for 3 months
- fever and night sweats but no loss of weight
- Underwent inguinal lymph node biopsy
- PET CT: FDG-avid lesions in R inguinal LN and R external iliac nodes. No other lesions
- Bone marrow biopsy: negative

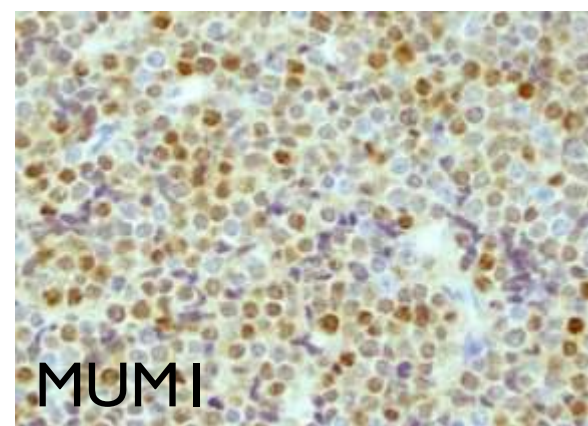
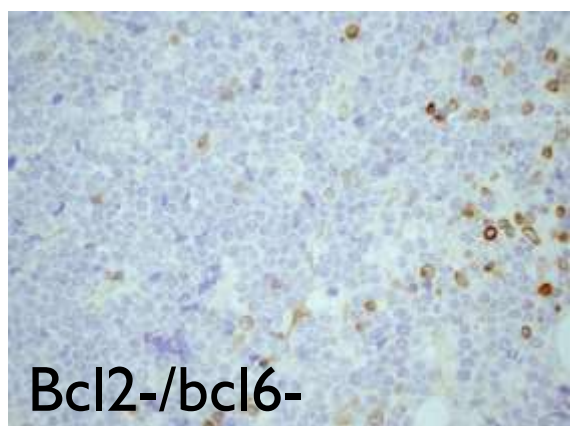
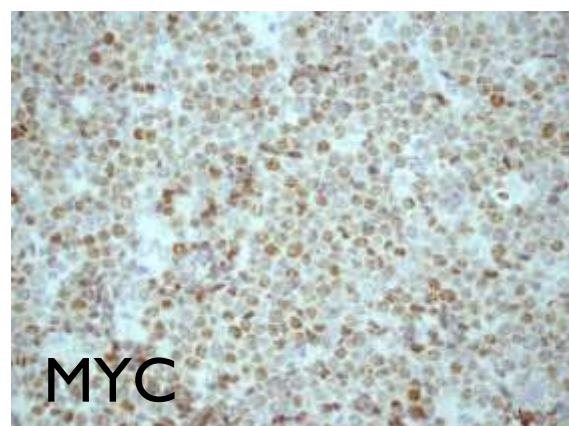
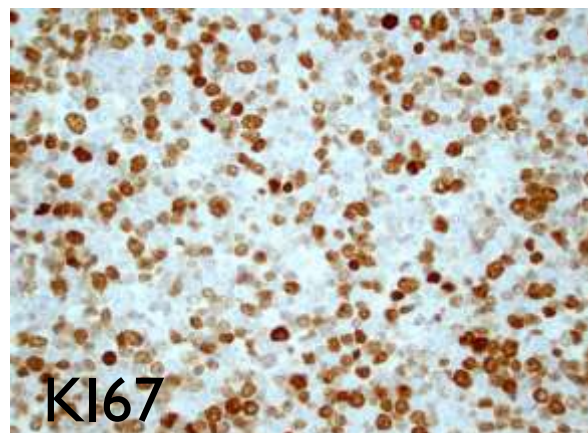
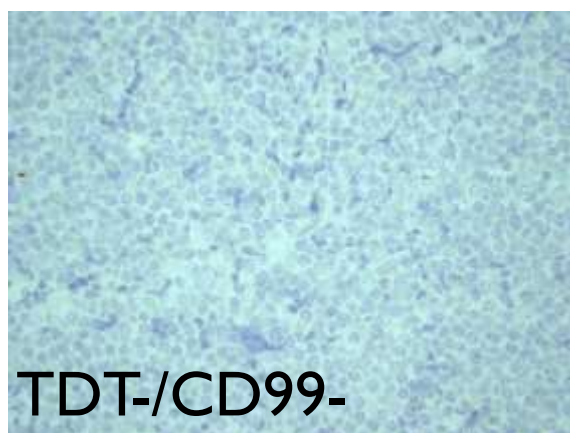
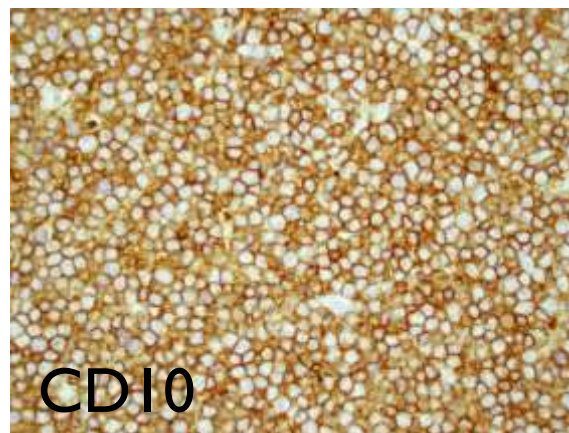
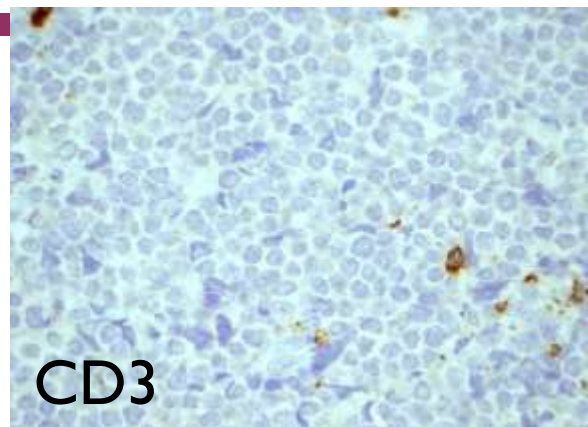
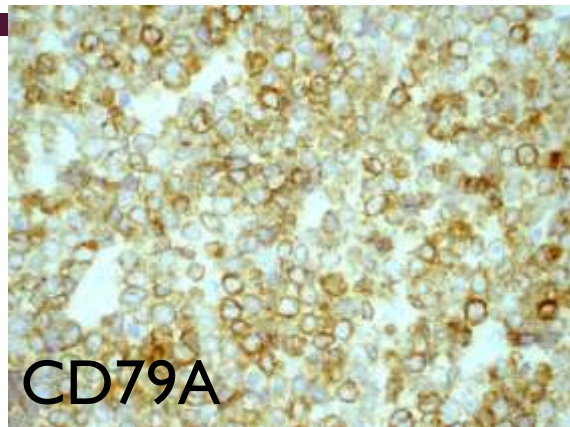
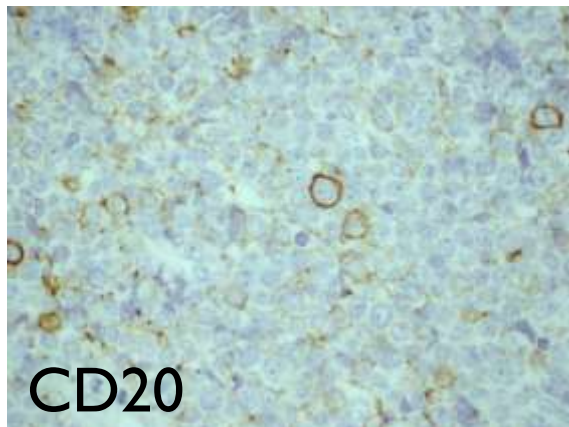


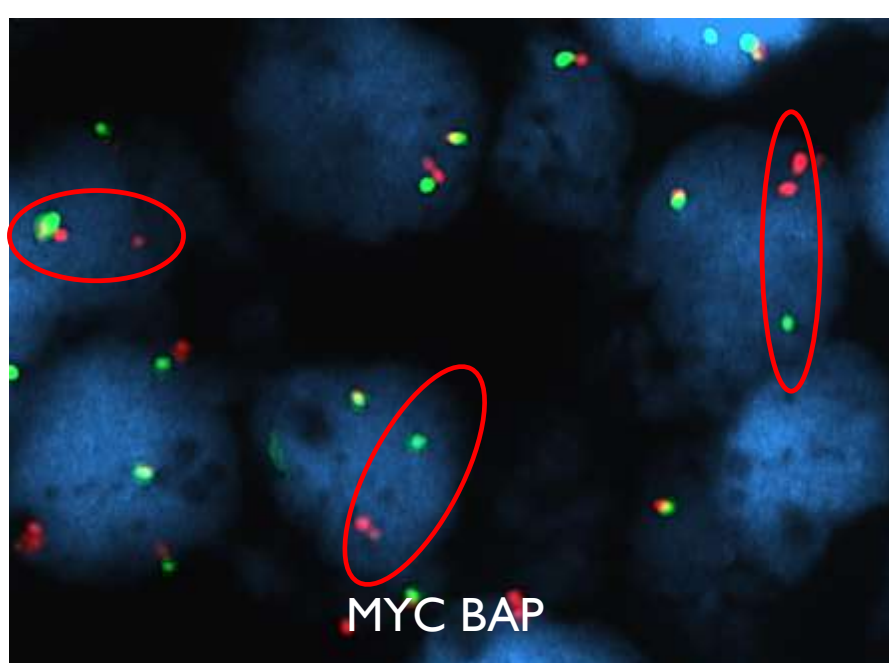
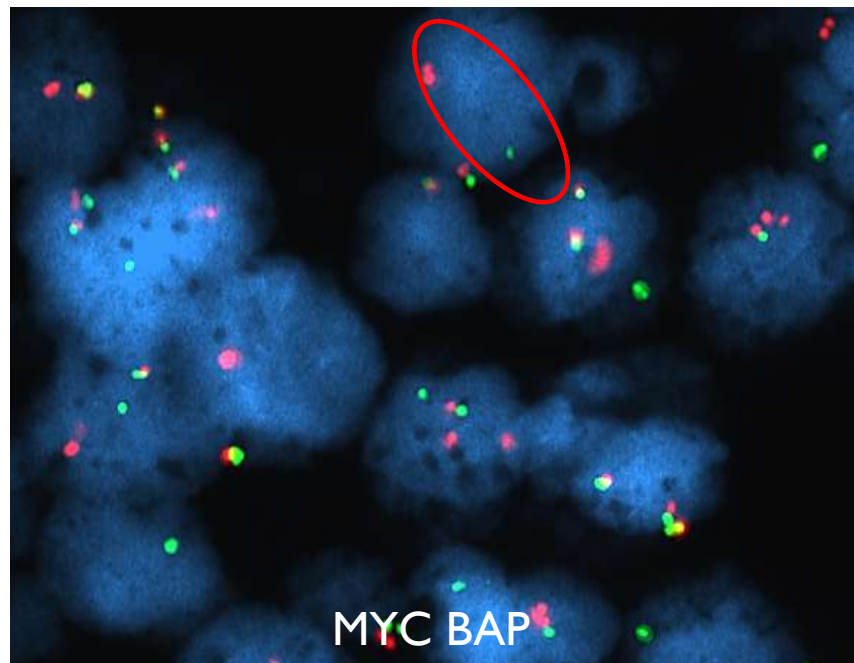
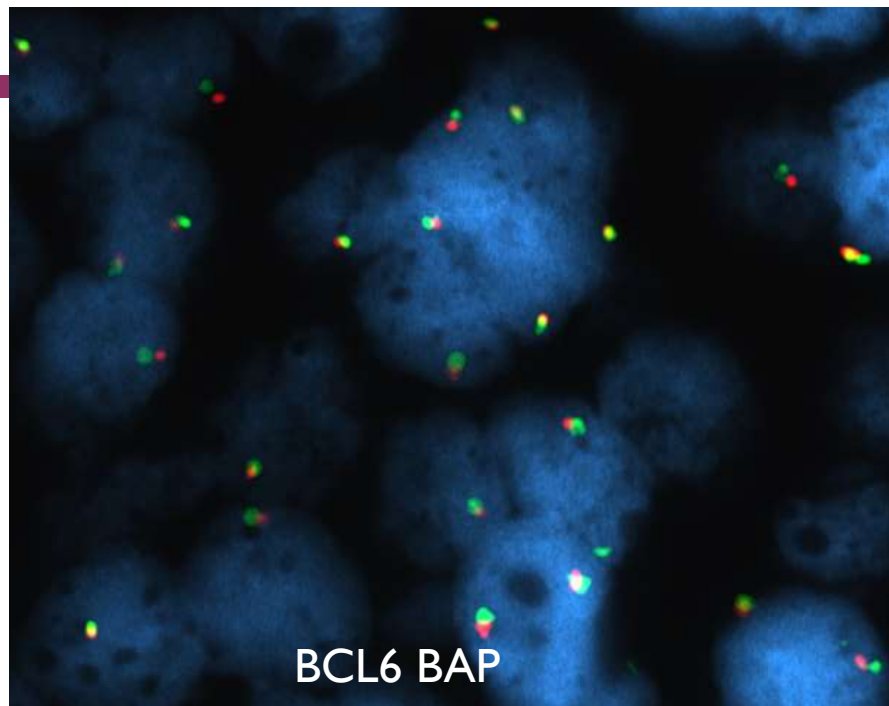
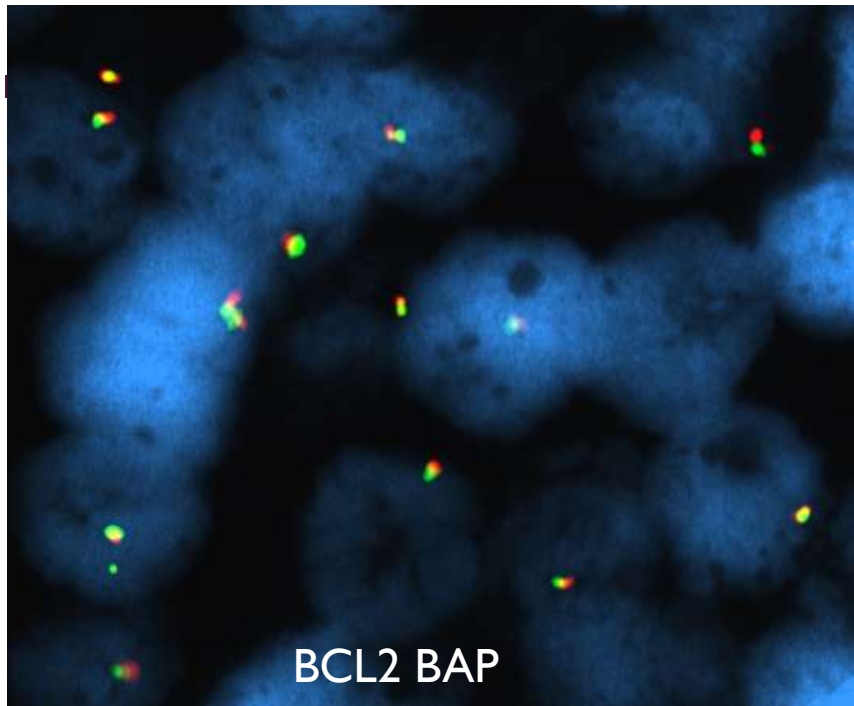
Diffuse lymphoid infiltrating adipose tissue



Lymphoid cells with blastoid morphology





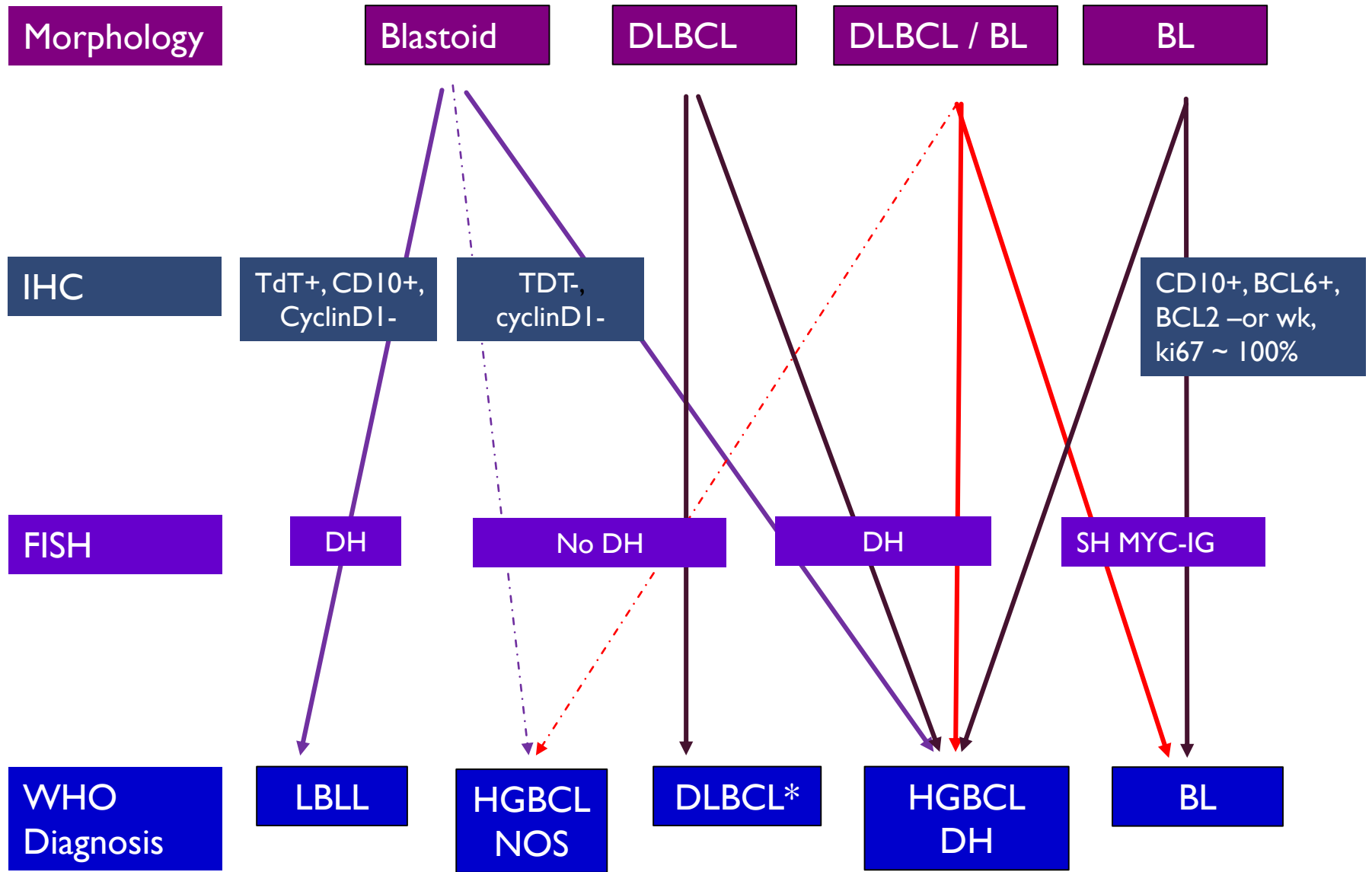


CASE 6 - SUMMARY

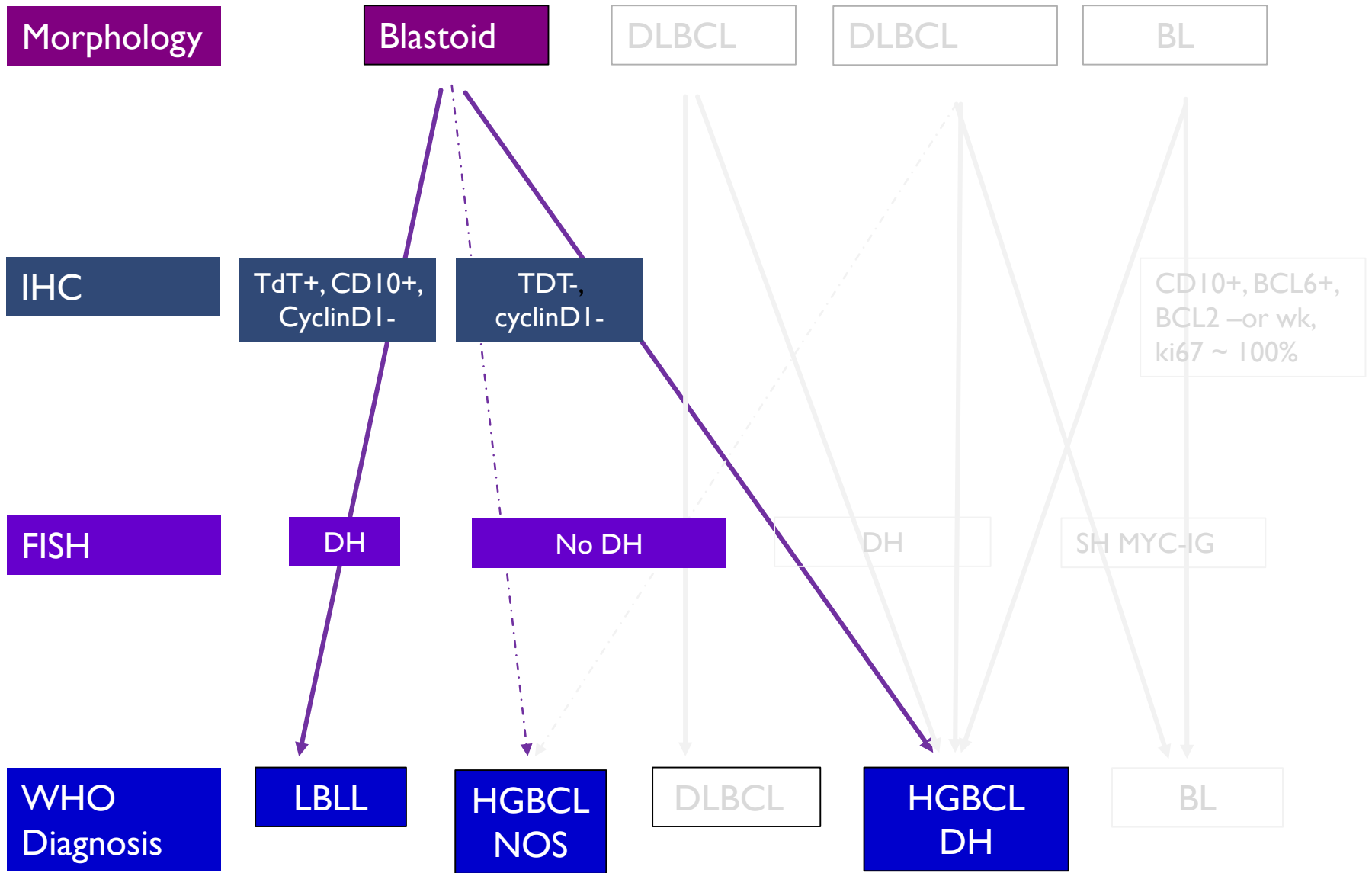
- B cell lymphoma with blastoid morphology
- IHC: MYC++, CD10+, BCL2-, BCL6-, TDT-, CD99-, CD5-
- High Ki67
- Loss of CD20
- MYC translocation
- No BCL2/BCL6 translocation

What's the diagnosis ?

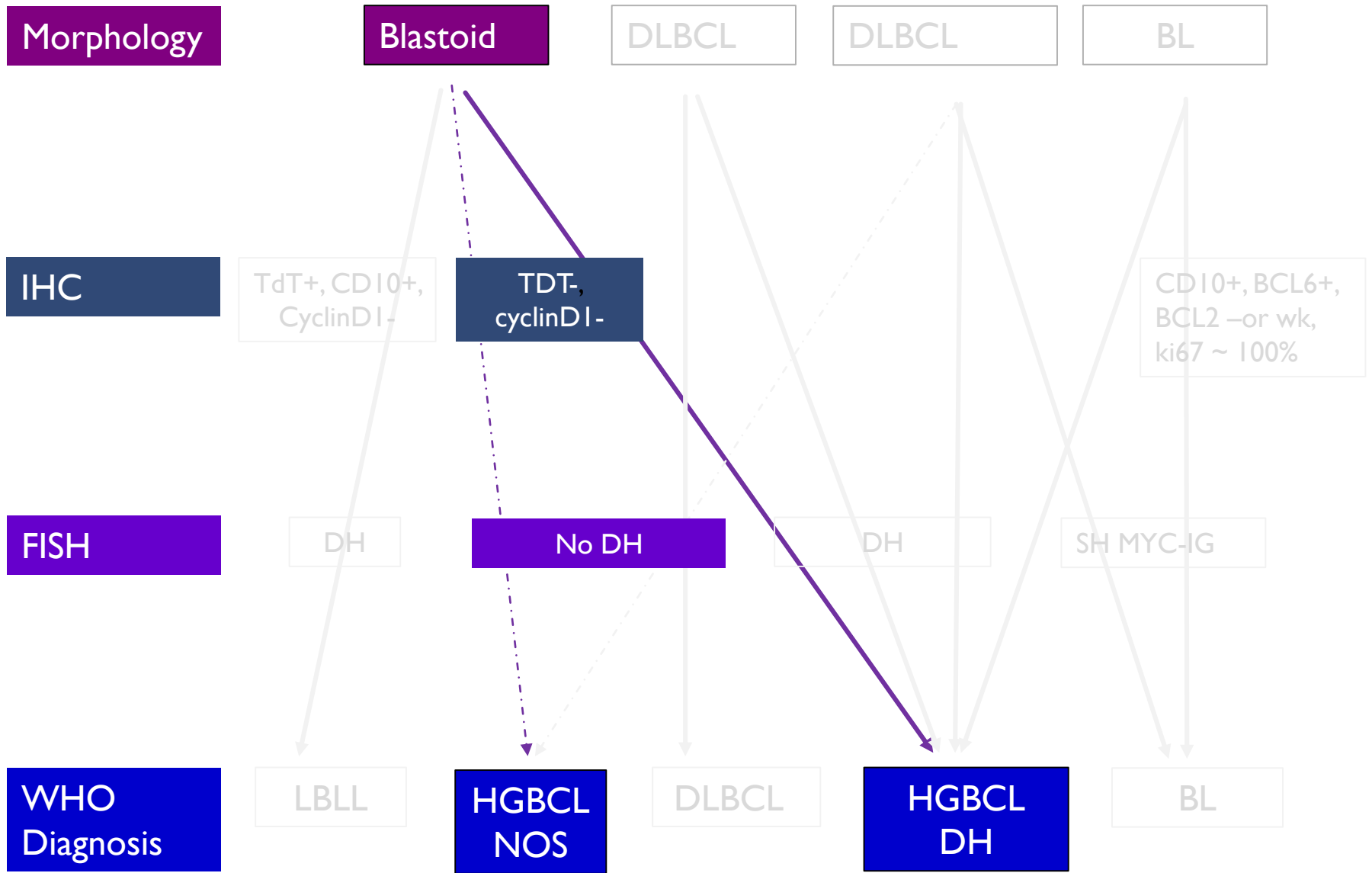
- A. Blastoid mantle cell lymphoma
- B. BL
- C. DLBCL
- D. HGBCL NOS



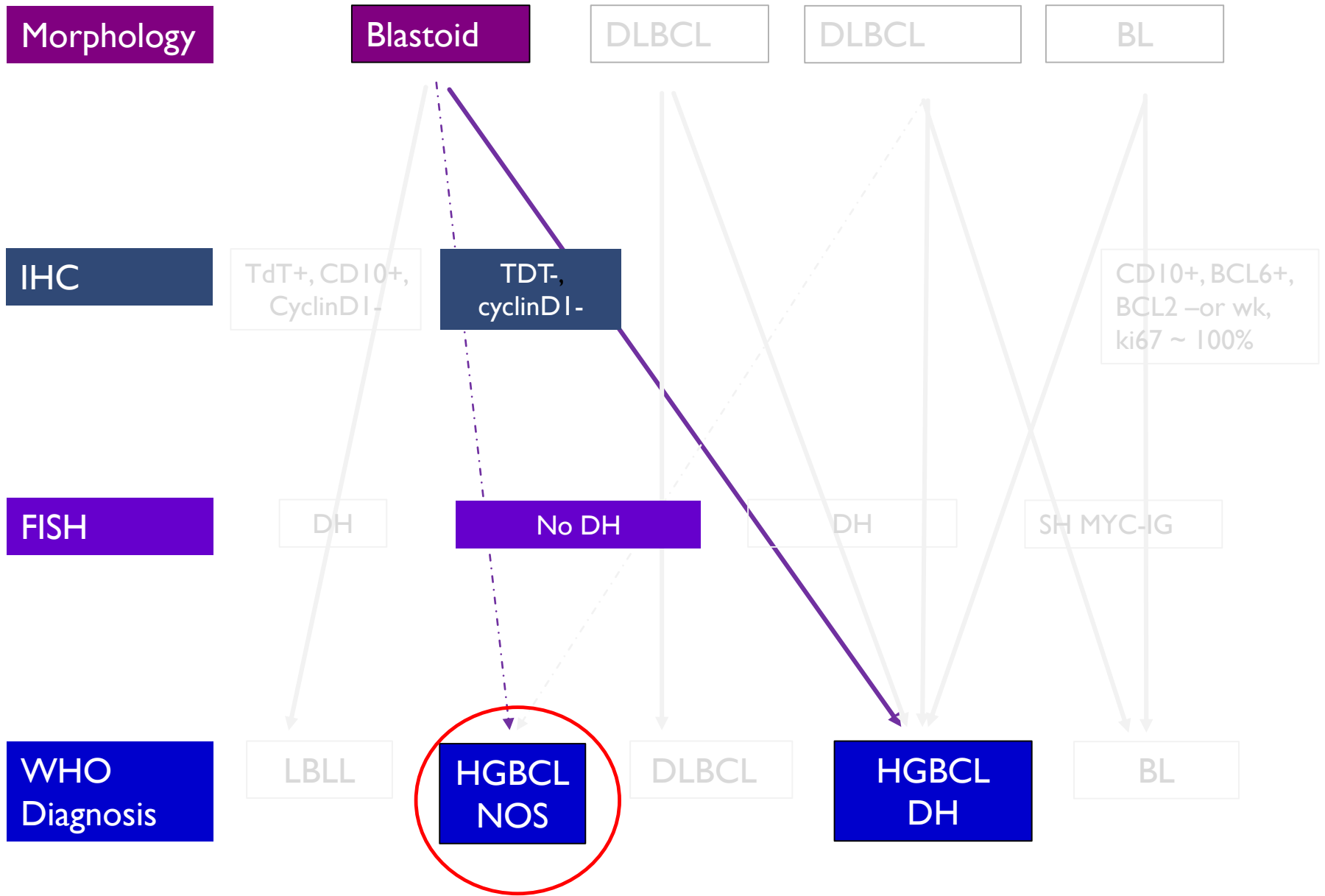
*Includes single MYC-translocation, LBLL;lymphoblastic lymphoma



*Includes single MYC-translocation, LBLL;lymphoblastic lymphoma



*Includes single MYC-translocation, LBLL;lymphoblastic lymphoma



*Includes single MYC-translocation, LBLL;lymphoblastic lymphoma